

Giant cell tumour of distal ulna

Akshay Phadke*, Kriti Handa, Chandrashekhar Badole and Anil Godara

Mahatma Gandhi Institute of Medical Sciences, Sevagram (MGIMS), Wardha, Maharashtra 442102 India

*Correspondence Info:

Dr. Akshay Phadke

Mahatma Gandhi Institute of Medical Sciences,

Sevagram, Wardha, Maharashtra 442102 India

E-mail: akshayphadke@mgims.ac.in

Abstract

Tumours of distal ulna are rare and its treatment is complicated by proximity of the distal radio-ulnar joint and the carpus. We report the case of a 35 year old male with giant cell tumour of the distal ulna treated by wide resection of distal ulna, fixation of iliac bone graft to distal end of radius and stabilisation of distal ulnar stump by tenodesis. At one year follow up patient had pain free movements of the wrist and did not have any recurrence.

Keywords: Giant cell tumor; distal ulna; DRUJ; Benign tumour of distal ulna; reconstruction of DRUJ.

1.Introduction

Giant cell tumour (GCT) is a benign but locally aggressive bone tumour occurring in adults in age group of 20- 40 years, rarely seen in patients older than 65 years. Common sites of occurrence of giant cell tumour are the distal femur and proximal tibia. Giant cell tumour of distal ulna occurs rarely, accounting for 0.5 to 2.9 % of all giant cell tumours.[1,2]

The treatment of Enneking stage 1 and stage 2 GCT consists of complete tumour removal with preservation of adjacent structures which is achieved by extended curettage. Due to high rate of recurrence wide resection is reserved for stage 3 tumours.[3,4] The treatment of GCT of distal ulna is less frequently reported in literature as its occurrence is rare.[5] The proximity of distal radioulnar joint and carpal bones makes the treatment of this tumour challenging.

2. Case report

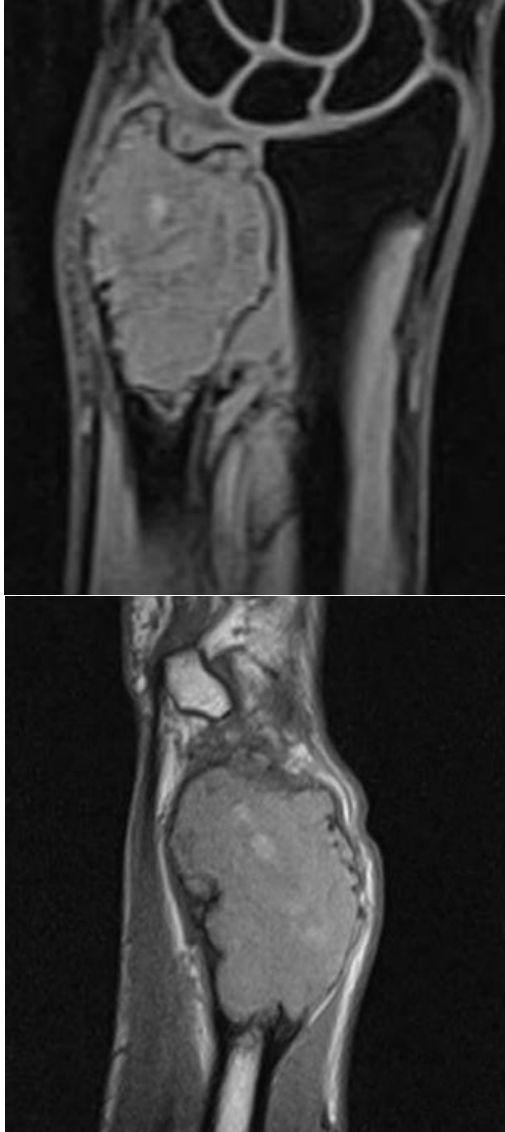
A 35 year old male presented with a painful gradually increasing swelling of 4 cm at dorso-ulnar aspect of right wrist. Skin was freely mobile and elastic. Wrist examination showed range of motion of 60 degrees of flexion, 30 degrees of extension, 10 degrees of ulnar and radial deviation. Supination, pronation and circumduction was painful. Plain radiograph of wrist showed a lytic lesion involving distal ulna with expansion and ballooning of cortex without any periosteal reaction. An area of cortical bone interruption was also seen. MRI showed

heterogenous signal intensity mass of size 5 x 3.5 x 3 cm with heterogeneously enhancing solid area and peripherally enhancing cystic area containing fluid-fluid level within in distal part of right ulna reaching upto articular surface causing its expansion with cortical thinning. A diagnosis of giant cell tumour was made which was confirmed on biopsy. The tumour was graded as stage 3 (aggressive) on Enneking's staging system for benign tumours.

Figure 1: Preoperative plain X-ray showed an expansile and radiolucent in the distal end of the left ulna

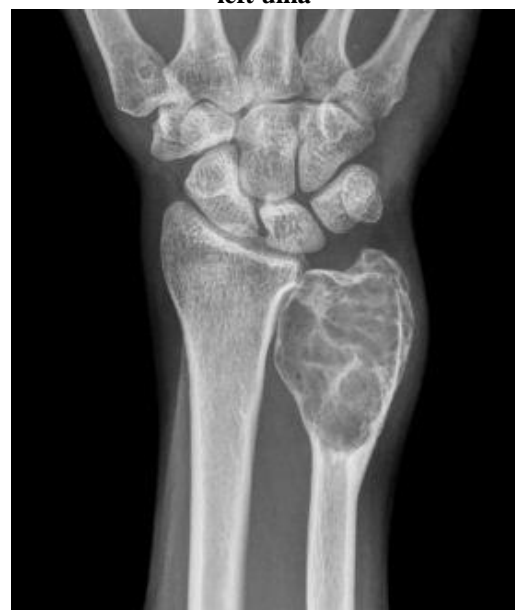

Figure 2: MRI showed heterogeneously enhancing solid area and peripherally enhancing cystic area containing fluid-fluid level within in distal part of right ulna reaching upto articular surface



Different treatment options were discussed with the patient and surgery was planned after obtaining a written informed consent from the patient. Enbloc resection of the distal ulna including healthy proximal bone was done with careful dissection of the ulnar foveal attachment of the triangular fibrocartilagenous ligament. Iliac bone graft was harvested and fixed to the ulnar side of the radial sigmoid notch with a small CC screw. An attempt to stabilise the distal end of the ulnar stump was done with split extensor carpi ulnaris tendon as follows. A drill hole was made with 3.2 mm drill bit, 1 cm proximal to the distal end of ulna and a slip of the tendon was passed through the ulnar medullary canal and the drill hole and sutured back to itself. Wound was closed in layers over a negative suction drain. Postoperatively a slab was given for three weeks in supination to immobilise the wrist joint after which physiotherapy was commenced.

IJBAR (2015) 6 (08)

Figure 3: Intra operative photograph showing tumor mass

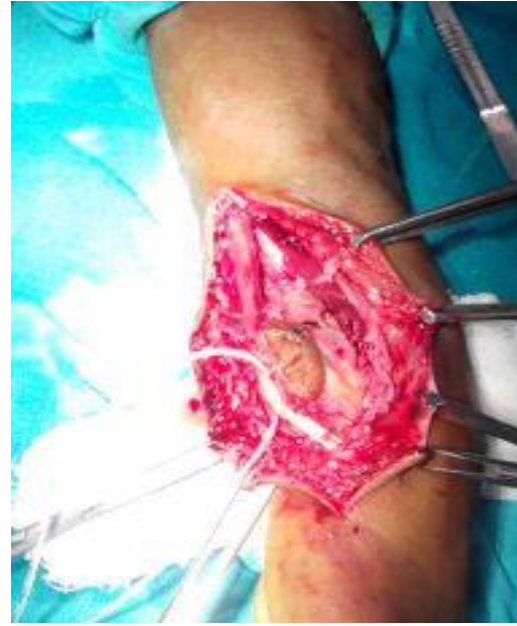
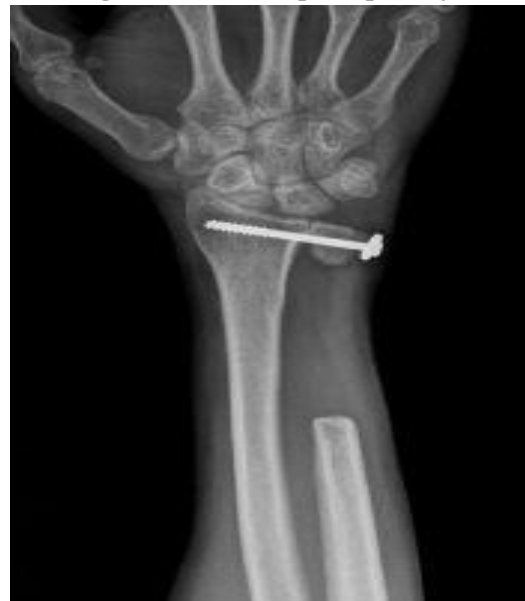
Figure 4: 6 months post op X-ray.



1 year post operatively patient had no pain, no instability and had returned to his occupation. His flexion – extension and supination - pronation movements were full and pain free. There was no evidence of recurrence of tumour.

3. Discussion

Giant cell tumour is a locally aggressive tumour and treatment depends on the stage of tumour and its location. Being a rare site, literature on treatment of tumours of distal ulna is limited. Treatment should be directed towards achieving complete removal of pathological tissue to avoid recurrence with maximum possible preservation of joint function.

www.ssjsournals.com

Cooney *et al*[6] achieved excellent results in 6 out of 8 patients treated with en bloc excision of distal ulna without reconstruction and concluded that routine reconstruction of the osseous defect is not necessary after en bloc resection of a neoplasm of the distal end of the ulna.

Many authors have described complete resection of distal ulna or ulnar shortening procedures for degenerative conditions. Classic Darrach resection (complete removal of ulna head) gives suboptimal results due to (“winging”) of the distal ulna stump secondary to loss of ulna-sided carpal support, TFCC disruption, and mechanical impingement (grinding contact) between distal ulna and the medial border of the radius.[7] Sauvé-Kapandji procedure involves arthrodesis of the DRUJ and creation of a pseudarthrosis at the distal neck of the ulna to allow dissipation of energy through forearm rotation. With arthrodesis the bony support to the carpus is widened medially.[8] But the Sauvé-Kapandji procedure suffers from complications similar to Darrach resection. Kleinman and Greenberg obtained satisfactory results using 50 % of extensor carpi ulnaris as longitudinal tenodesis and pronator quadratus interposition to retard impingement and winging.[9]

Hashizume *et al* described an ulnar buttress arthroplasty for reconstruction after resection of the distal ulna for giant cell tumour.[10] Stabilisation by extensor tendon tenodesis after removal of tumour was described by Kayias *et al* with excellent functional results.[11]

Fixation of an iliac crest graft to the distal radius provides medial support and restores anatomy of the DRUJ. The triangular fibro-cartilage can be attached to the graft improving stability. The distal end is stabilised by tenodesis preventing impingement. Thus the combination of these two procedures has resulted in a satisfactory functional outcome in our case.

References

- [1] Beebe-Dimmer JL, Cetin K, Fryzek JP, Schuetze SM, Schwartz K. The epidemiology of malignant giant cell tumors of bone: an analysis of data from the Surveillance, Epidemiology and End Results Program (1975-2004). *Rare Tumors* [Internet]. 2009 Jan [cited 2015 Aug 7];1(2):e52. Available from: <http://www.pubmedcentral.nih.gov/articlerender.fcgi?artid=2994468&tool=pmcentrez&rendertype=abstract>
- [2] Goldenberg RR, Campbell CJ, Bonfiglio M. Giant-cell tumor of bone. An analysis of two hundred and eighteen cases. *J Bone Joint Surg Am* [Internet]. 1970 Jun [cited 2015 Jul 22];52(4):619–64. Available from: <http://www.ncbi.nlm.nih.gov/pubmed/5479455>
- [3] Campanacci M, Baldini N, Boriani S, Sudanese A. Giant-cell tumor of bone. *J Bone Joint Surg Am* [Internet]. 1987 Jan [cited 2015 Aug 7];69(1):106–14. Available from: <http://www.ncbi.nlm.nih.gov/pubmed/3805057>
- [4] Enneking WF. A system of staging musculoskeletal neoplasms. *Clin Orthop Relat Res* [Internet]. 1986 Mar [cited 2015 Jul 24];(204):9–24. Available from: <http://www.ncbi.nlm.nih.gov/pubmed/3456859>
- [5] Singh M, Sharma S, Peshin C, Wani IH, Tikoo A, Gupta SK, *et al*. Wide resection and stabilization of ulnar stump by extensor carpi ulnaris for giant cell tumor of distal ulna: two case reports. *Cases J* [Internet]. 2009 Jan [cited 2015 Aug 7];2(1):8617. Available from: <http://www.casesjournal.com/content/2/1/8617>
- [6] Cooney WP, Damron TA, Sim FH, Linscheid RL. En bloc resection of tumors of the distal end of the ulna. *J Bone Joint Surg Am* [Internet]. 1997 Mar [cited 2015 Aug 8];79(3):406–12. Available from: <http://www.ncbi.nlm.nih.gov/pubmed/9070531>
- [7] Chu P-J, Lee H-M, Hung S-T, Shih J-T. Stabilization of the proximal ulnar stump after the Darrach or Sauvé-Kapandji procedure by using the extensor carpi ulnaris tendon. *Hand (N Y)* [Internet]. 2008 Dec [cited 2015 Aug 8];3(4):346–51. Available from: <http://www.pubmedcentral.nih.gov/articlerender.fcgi?artid=2584221&tool=pmcentrez&rendertype=abstract>
- [8] Lluch A. The sauvé-kapandji procedure. *J Wrist Surg* [Internet]. 2013 Feb [cited 2015 Aug 8];2(1):33–40. Available from: <http://www.pubmedcentral.nih.gov/articlerender.fcgi?artid=3656576&tool=pmcentrez&rendertype=abstract>
- [9] Kleinman WB, Greenberg JA. Salvage of the failed Darrach procedure. *J Hand Surg Am* [Internet]. 1995 Nov [cited 2015 Aug 8];20(6):951–8. Available from: <http://www.ncbi.nlm.nih.gov/pubmed/8583067>
- [10] Hashizume H, Kawai A, Nishida K, Sasaki K, Inoue H. Ulnar buttress arthroplasty for reconstruction after resection of the distal ulna for giant cell tumour. *J Hand Surg Br* [Internet]. 1996 Apr [cited 2015 Aug 8];21(2):213–5. Available from: <http://www.ncbi.nlm.nih.gov/pubmed/8732404>
- [11] Kayias EH, Drosos GI, Anagnostopoulou GA. Resection of the distal ulna for tumours and stabilisation of the stump. A case report and literature review. *Acta Orthop Belg* [Internet]. 2006 Aug [cited 2015 Aug 8];72(4):484–91. Available from: <http://www.ncbi.nlm.nih.gov/pubmed/17009832>