
Cystecercosis of foot: A rare diagnosis in a rare location

Parvataneni Prathap*, Anil Kumar S.V, Nagakumar J.S, Vineetha Vittal and Manohar P.V

Sri Devraj Urs Medical College, Tamaka, Kolar, Karnataka 563101 India

*Correspondence Info:

Dr. Parvataneni Prathap

Sri Devraj Urs Medical College,

Tamaka, Kolar, Karnataka 563101 India

E-mail: prathap_parvataneni@yahoo.com

Abstract

Cysticercosis is an infection caused by the larval form of tape worm *Taenia Solium*. This infection commonly presents with central nervous system involvement. Here we present a case of isolated cystecercosis of foot diagnosed on Magnetic Resonance Imaging (MRI). The case was successfully managed conservatively.

Keywords: cystecercosis, tape worm, foot, albendazole, MRI

1. Introduction

Cysticercosis infection in humans is caused by *Taenia Solium*[1]. The cysts occur first in central nervous system² followed by the eye, striated muscles, subcutaneous tissue and rarely in other locations. To our knowledge presence of isolated

cystecercosis infection in rare[3-6]. Now we present this case of isolated cystecercosis of foot which was diagnosed accurately on Magnetic Resonance Imaging (MRI) and resolved successfully on treatment with albendazole.

All the blood counts were normal. Erythrocyte sedimentation rate was elevated 75mm/hr. No other positive laboratory reports were present.

2. Case Report

A 22 yrs old female medical student presented to our outpatient department with complains of pain and swelling on the plantar and dorsal aspect of left foot for a week.

MRI foot showed small cystic scolex shaped lesion measuring 8mm in the plantar aspect deep to flexor tendons at the level of 2nd metatarsal with a hypo tense focus and associated collection, possibility of soft tissue cystecercosis.

Patient doesn't give any history of trauma to the foot. Initially she managed the symptoms with analgesics with which the symptoms did not relieve completely and had persistent swelling.

Computerised tomography (CT SCAN) of brain of has been done to rule out any cerebral lesions. Report showed normal brain study.

There were no other constitutional symptoms. No history of consumption of beef or pork meat and no contact with any animal. She is a predominantly vegetarian on diet.

Patient was managed conservatively with anti-helmentic drug Albendazole 15mg/kg/day in two divided doses for three weeks, diclofenac as an analgesic. She was given one dose of dexamethasone 4mg injection intra muscularly. Patient was followed on every third day for three weeks. Pain and edema of foot subsided in a week. Swelling gradually reduced in three weeks' time. After one and half month patient was completely relieved of symptoms.

On examination there was erythema and edema to the skin over the dorsal and plantar aspect of the foot. On palpation of swelling there was no local rise of temperature, it was a tender globular swelling of 3x2cm with undefined margins. Swelling was non pulsatile, non adherent to skin. The size and shape of the swelling hasn't changed with movements of ankle, subtalar and mid tarsal joints and movements of joints are complete.

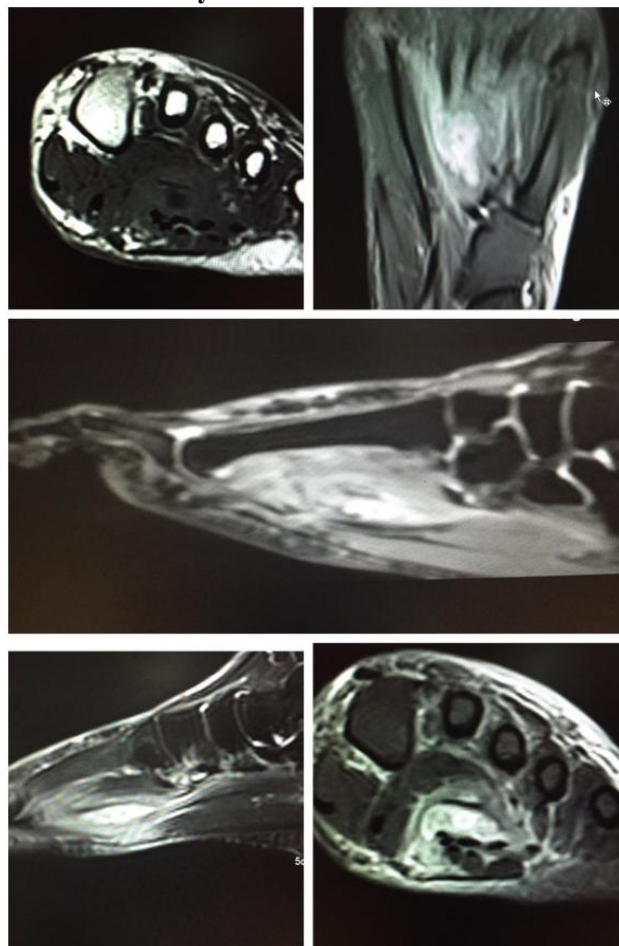
Figure 1: Clinical photographs showing edema of foot and cystic swelling

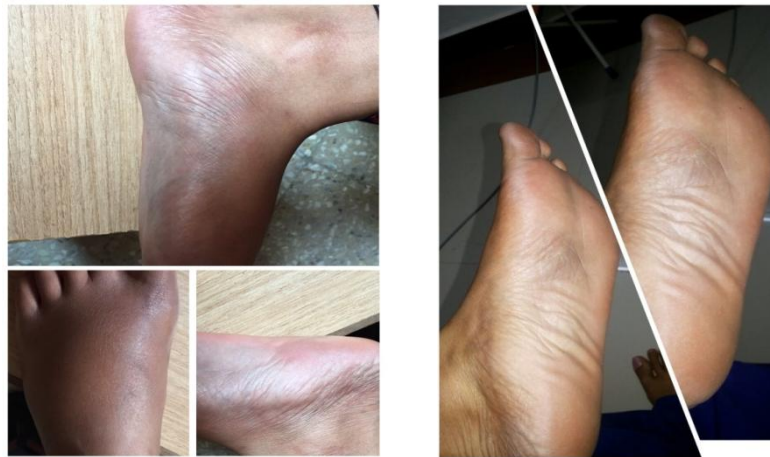

Figure 2: Oblique and antero-posterior radiographs of foot

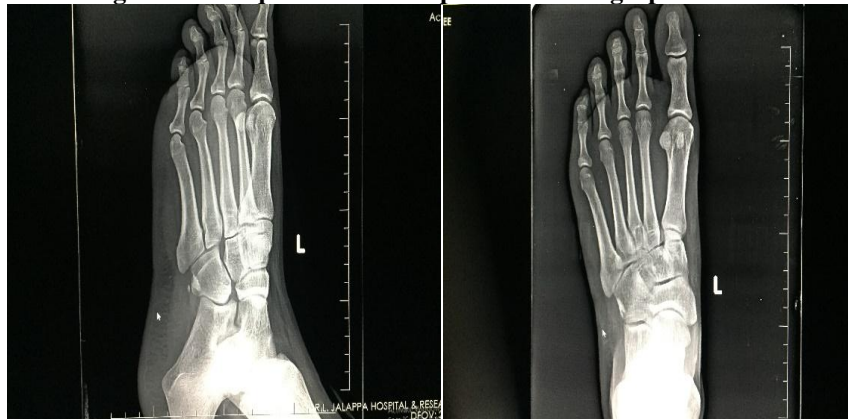

Figure 3: MRI Images both sagittal and coronal sections showing scolex shaped cystic lesions suggestive of soft tissue cystecercosis with associated abscess



3. Discussion

Cystecercosis infection in humans is caused by *Taenia Solium*[1]. It is common in Asians (mostly Indians) and African population where the pigs are raised for consuming purpose and socio economic status is low[7].

In the life cycle of tape worm humans are the definitive host for tape worm infection and the tape worm enters humans generally through inadequately pork or beef consumption. Ingested eggs hatch in the small intestine, releasing oncospheres that penetrate the bowel mucosa and enter the bloodstream to travel to various tissues where they develop to form an encysted larval form of *T. Solium* known as cysticercosis cellulosae. When the larva dies, it induces an aggressive granulomatous inflammatory response, leading to characteristic organ-specific symptoms.

The cysts occur first in central nervous system followed by the eye, striated muscles, subcutaneous tissue and rarely in other locations. Presence of multiple muscular cysts and isolated involvement in foot is rare. So this case can be considered as a rare disease at a rare location.

Mostly this type of cystecercosis infection in foot is a rare in possibility. This is the first case in 25 years from the department of orthopaedics existence in R.L Jalappa Hospital, Tamaka, Kolar.

This case mostly goes unnoticed and will be asymptomatic. The swelling in due to release of antigens after the death of disease. In our case any trivial trauma to the foot in the region of cyst which was unnoticed might have caused the release of antigens resulting in death of inflammation.

Three different clinical manifestations of muscular cysticercosis are described: myalgic myopathic type; the nodular or mass like type; and the pseudohypertrophy type in which multilocular cyst formation occurs in group of muscle[8][9]. The myalgic type results from death of the cyst and leakage of fluid leading to inflammation. The nodular type or pseudotumor type both result from degeneration of the cyst and slow intermittent leakage of fluid over time, leading to a chronic inflammatory response with collection of fluid around the cyst producing a mass. This case is a myalgic variant.

Del Brutto *et al* proposed diagnostic criteria for human cysticercosis[10]. They suggested that apart from Immunochemical studies (including detection of anticysticercal antibodies), CT and MRI are important tools in diagnosis. Although MRI is more specific for neurocysticercosis, CT may be the modality of choice for muscle cysts as it can demonstrate multiple cysts in a honeycomb or

leopard skin pattern against a background of muscle mass.

Treatment of cystecercosis depends on the site involvement. It is generally treated with anti-parasitic drugs in combination with inflammatory drugs[11]. Surgery is sometimes necessary to treat cysts in certain locations when patient is not response to drug treatment. Even if you don't treatment to treat parasite, you may need treatment for the symptoms caused by the infection, such as medication to reduce of seizures you have.

Albendazole acts by inhibiting microtubule formation. The loss of cytoplasmic microtubules blocks glucose uptake in the larval and adult stages of the parasites, thereby depleting their energy reserves and causing death; So treatment with albendazole along with anti inflammatory successfully helped in resolving the disease.

4. Conclusion

So here Cystecercosis of foot is a rare diagnosis in a rare location which was successfully treated non operatively with use of albendazole and anti inflammatory drugs.

References

- [1] Garcia HH, Gonzalez AE, Evans CA and Gilman RH. *Taenia solium* cysticercosis. *Lancet*. 2003; 362:547-56.
- [2] Ogilvie CM, Kasten P, Rovinsky D, Workman KL and Johnston JO. Cysticercosis of the triceps--an unusual pseudotumor: case report and review. *Clin Orthop Relat Res*. 2001; 217-21.
- [3] Kumar BD, Dave B and Meghana SM. Cysticercosis of masseter. *Indian J Dent Res*. 2011; 22:617.
- [4] Kumar R, Singh V and Rastogi A. Cysticercosis of temporalis muscle: a case report. *J Pediatr Neurol*. 2005; 3:269-72.
- [5] Nagaraj C, Singh S, Joshi A and Trikha V. Cysticercosis of biceps brachii: a rare cause of posterior interosseous nerve syndrome. *Joint Bone Spine*. 2008; 75:219-21.
- [6] Sharma R, Gautam P, Kumar S, Elhence P, Bansal R and Gupta G. Isolated cysticercosis cellulosae of sternocleidomastoid muscle: a case report with review of literature. *Indian J Otolaryngol Head Neck Surg*. 2011; 63:127-30.
- [7] Holzapfel BM, Schaeffeler C, Banke IJ and Waldt S. A 37-year-old man with a painless growing mass of the thorax. *Clin Orthop Relat Res*. 2010; 468:1193-8.
- [8] Horton J. Biology of tapeworm disease. *Lancet*. 1996; 348:481.
- [9] Mittal A, Das D, Iyer N, Nagaraj J and Gupta M. Masseter cysticercosis- a rare case diagnosed on ultrasound.
- [10] Del Brutto OH, Wadia NH, Dumas M, Cruz M, Tsang VC and Schantz PM. Proposal of diagnostic criteria for human cysticercosis and neurocysticercosis. *J Neurol Sci*. 1996; 142:1-6.
- [11] Mohan K, Saroha V, Sharma A, Pandav S and Singh U. Extraocular muscle cysticercosis: clinical presentations and outcome of treatment. *J Pediatr Ophthalmol Strabismus*. 2005; 42:28-33.