

**International Journal of Biomedical and Advance Research**

ISSN: 2229-3809 (Online); 2455-0558 (Print)

Journal DOI: [10.7439/ijbar](https://doi.org/10.7439/ijbar)

CODEN: IJBABN

**Case Report**

---

**Cervical Pregnancy: A Dilemma for Diagnosis and Management**

---

**Prasad Lele<sup>\*1</sup>, MK Tangri<sup>2</sup> and H Bal<sup>3</sup>**<sup>1</sup>Senior Advisor (Obs & Gyn), Reproductive Medicine Specialist, Command Hospital (SC)<sup>2</sup>Classified Spl (Obs & Gyn), Gynaecologist, Command Hospital (SC)<sup>3</sup>Professor (Obs & Gyn), DY Patil Medical College, Pimpri, Pune.**\*Correspondence Info:**

Dr. Prasad Lele, MS, DNB  
Senior Advisor (Obs & Gyn),  
Reproductive Medicine Specialist,  
Command Hospital (SC), India  
E-mail: [prasadlele@hotmail.com](mailto:prasadlele@hotmail.com)

**Abstract**

Cervical ectopic presents as diagnostic dilemma because of its resemblance to abortion process. We present couple of cases of Cervical ectopic and discuss the management for this diagnostic dilemma.

**Keywords:** cervical ectopic, ultrasonography

**1. Introduction**

Cervical pregnancy results from implantation of the embryo in the endocervical canal.[1] It presents as a diagnostic dilemma because of its resemblance to the abortion process and if managed by curettage can lead to unexpected haemorrhage and emergency hysterectomy. We came across couple of cases with cervical ectopic pregnancy that were diagnosed on a first-trimester ultrasound examination.

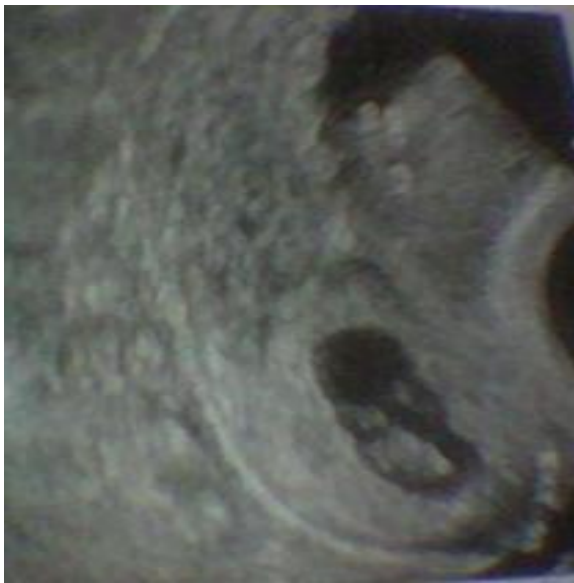**2. Case reports****2.1 Case report 1**

A 28-year-old presented with 10 weeks of amenorrhea and painless bleeding per vaginum. On examination we found an 8 weeks size uterus with distended cervical region and closed external os. The urine pregnancy test (UPT) was positive and ultrasound showed a gestational sac with no cardiac activity in the cervical region. The patient was diagnosed as incomplete abortion and was posted for dilatation and evacuation. On evacuation we encountered heavy bleeding that was managed by carboprost with Foley's balloon tamponade. Foley's catheter was removed after 36 hrs. Patient had an uneventful recovery.

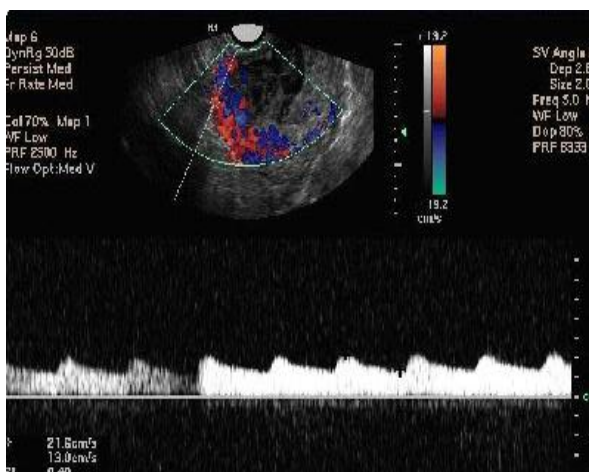
**2.2 Case report 2**

A 32-year-old Gravida 6 Para 1 Abortion 4 presented with 9 weeks of amenorrhea and painful bleeding per vaginum on and off since 1 week. On examination we found an 8 weeks size uterus with distended cervical region and closed external os. The urine pregnancy test (UPT) was positive and ultrasound showed a gestational sac with no cardiac activity in the cervical region (Figure 1). Armed with previous experience possibility of cervical ectopic was considered and color doppler studies were done which showed increased peritrophoblastic flow in the cervical region. Patient was diagnosed to have cervical ectopic. A conservative medical management was planned and patient was given Inj methotrexate 50 mg on alternate days for four days with folic acid rescue. Patient continued to have spotting per vaginum for next 8 days. At her insistence she was posted for dilatation and evacuation. Prophylactic Foley's balloon tamponade was given for 24 hrs. Post evacuation patient had uneventful recovery.

**Figure 1: USG showing gestation sac in cervical region in case no 2**



**Figure 2: Increased peritrophoblastic blood flow around conceptus seen in the second case**



### 3. Discussion

Cervical pregnancies, before ultrasound era were diagnosed by criteria laid down by Rubin[1] in a 1911 case report. The incidence is between 1/1000 to 1/18,000 live births and less than 1% of ectopic pregnancies are cervical.[2] Migration of the fertilized ovum, change in the ability of the endometrial lining to accept implantation, damage to the endocervical canal and in vitro fertilization may all be contributing factors.[3][4] Several studies have shown a high incidence of prior dilatation and curettage (D&C) among women with cervical pregnancies[3] as seen in our second case had underwent two to four induced abortions with D&C.

Presentation is classically painless first-trimester vaginal bleeding, but cramping pain like in

our second case may be present. This presents the diagnostic dilemma in differentiating it from incomplete abortion. Clinically a soft cervix that is disproportionately enlarged compared with the uterus, a partially open external os, and profuse hemorrhage on manipulation of the cervix should suggest cervical pregnancy.[5] None of these signs are either diagnostic or invariably present and may confuse with cervical abortion. On suspicion of cervical pregnancy radiological evaluation is mandatory.

Raskin[6] suggested that the diagnosis by ultrasound examination of cervical pregnancy required four factors: enlargement of the cervix, uterine enlargement, diffuse amorphous intrauterine echoes, and absence of intrauterine pregnancy. All these were present in our series. Subsequently Timor-Tritsch *et al*[7] added more stringent criteria: the placenta and entire chorionic sac containing the live pregnancy must be below the internal os and the cervical canal must be dilated and barrel shaped which is difficult to note. Jurkovic *et al*[8] proposed two additional diagnostic criteria to distinguish cervical ectopic pregnancy from an aborting intrauterine pregnancy residing in the cervix. The "sliding sign" is detected on endovaginal ultrasound examination. This is elicited when the sonographer applies gentle pressure on the cervix with the probe, the gestational sac of an abortus slides against the endocervical canal. This sliding motion will not be found in an implanted cervical pregnancy. The second criterion is demonstration of peritrophoblastic blood flow from an active vascular supply to the conceptus with Color Doppler ultrasonography where abortus passing through the cervix will not have any peritrophoblastic flow, as it is separated from its vascular supply. This helped us to differentiate and arrive at the diagnosis in our series.

Treatment of cervical ectopic pregnancy depends on the fetal gestational age and the woman's desire to maintain fertility. The options may be divided conceptually into five categories: tamponade, reduction of blood supply, excision of trophoblastic tissue, intra-amniotic foeticide, and systemic chemotherapy.

Tamponade with use of an inflated balloon of Foley catheter, placed gently past the external os has proven to be more effective in achieving haemostasis than packing.[9][10] It is commonly used after other techniques, which may result in hemorrhage as in our first case where we resorted to this method after curettage.

Curettage and hysterectomy are classic techniques for removing cervical pregnancies. Curettage has the risk of hemorrhage, but if combined with mechanical techniques the risk is significantly reduced.[8][9][10] Primary hysterectomy may be appropriate in case of intractable hemorrhage, late presentation or when fertility is not desired.

Antineoplastic medications, most commonly used systemic agent is methotrexate with a reported success rate of more than 80%<sup>7</sup> especially at early gestational ages, HCG > 40,000 IU/L and presence of fetal cardiac activity. Single and multiple dose regimens, with and without folinic acid rescue, have been reported. It would be prudent to watch for a possible increased risk of preterm labor or incompetent cervix, while reassuring patients that most pregnancies after a cervical ectopic will lead to term deliveries.

#### 4. Conclusion

Cervical ectopic pregnancy is an uncommon entity, but with increasing incidence of abortions and use of assisted reproductive technology, surge in cervical ectopics has been observed. The ultrasound with color box helps in early diagnosis and its distinction from cervical abortion. Combined medical and surgical treatment allows the preservation of fertility and reduction in morbidity in these patients.

#### References

- [1] Rubin IC. Cervical pregnancy. *Surg Gynecol Obstet.* 1911; 13:625-633.
- [2] Samal SK, Rathod S. Cervical ectopic pregnancy. *J Nat Sc Biol Med* 2015; 6:257-60.
- [3] Shinagawa S, Nagayama M. Cervical pregnancy as a possible sequela of induced abortion. *Am J Obstet Gynecol.* 1969; 105:282-284.
- [4] Ginsburg ES, Frates MC, Rein MS, et al. Early diagnosis and treatment of cervical pregnancy in an in vitro fertilization program. *Fertil Steril.* 1994; 61:966-969.
- [5] Kirk E, Condous G, Haider Z, Syed A, Ojha K, Bourne T. The conservative management of cervical ectopic pregnancies. *Ultrasound Obstet Gynecol* 2006; 27:430-7.
- [6] Raskin MM. Diagnosis of cervical pregnancy by ultrasound: a case report. *Am J Obstet Gynecol.* 1978; 130:234-235.
- [7] Timor-Tritsch IE, Monteagurdo A, Mandeville EO, et al. Successful management of viable cervical pregnancy by local injection of methotrexate guided by transvaginal ultrasonography. *Am J Obstet Gynecol.* 1994; 17:737-739.
- [8] Jurkovic D, Hackett E, Campbell S. Diagnosis and treatment of early cervical pregnancy. *Ultrasound Obstet Gynecol.* 1996; 8:373-380.
- [9] Surampudi K. A case of cervical ectopic pregnancy: Successful therapy with methotrexate. *J Obstet Gynaecol India* 2012; 62 Suppl 1:1-3.
- [10] Guillermo A. De La Vega, Caudrean Avery. Treatment of Early Cervical Pregnancy with Cerclage, Carboprost, Curettage, and Balloon Tamponade. *Obstetrics & Gynecology* 2007; 109:505-507