

Ureterocele with unilateral duplex system: Presenting as severe urinary tract infection in an infant

Vinay S Kundargi, Nikhil A Patil*, Siddangouda B Patil, Ashok N Biradar, Kshitiz S Ranka and Anup S Desai

Department of Urology, Shri. B. M. Patil Medical College and Hospital & Research Centre, Bijapur, India

*Correspondence Info:

Dr. Nikhil Ashok Patil

Senior Resident

Department of Urology,

Shri. B. M. Patil Medical College and Hospital, Bijapur, India

E-mail: drpatilnikhil@yahoo.com

Abstract

Ureterocele is a cystic dilatation anomaly of distal ureter with an incidence of 1:500-2000 at childhood. Complete ureter duplication is primarily seen in ureter that drain upper pole by 80%. Ureterocele, vesicoureteral reflux (VUR) and ectopic ureter may be seen in association with duplicated collecting system anomaly and some syndromes can accompany to duplex system anomaly. Obstruction with very poor renal function is best treated by upper pole heminephroureterectomy. We report congenital ureterocele with non functioning upper moiety.

Keywords: Ureterocele duplicated collecting system, heminephroureterectomy.

1.Introduction

Ureterocele is dilatation of lower ureter at its entry into urinary bladder. It is classified as single or duplex system and acquired or congenital [1]. Acquired type is commonly seen in adults. Duplicated ureters are often associated with an obstructed upper pole moiety and a refluxing lower pole moiety [2]. In our case we report congenital ureterocele with non functioning upper moiety.

2. Case Report

A one year child presented with complaints of frank pyuria since 3 months. This was associated with 2 episodes of fever. Fever was of moderate degree and intermittent type. The physical, genital, and spinal examinations were unremarkable. Developmental milestones were within normal limits. Baby was underweight for his age. Complete blood count showed raised total leukocyte count. Urine routine showed plenty of pus cells. Serum creatinine was 1.2mg/dl. Citrobacter species was isolated from culture. Ultrasound abdomen showed left duplex kidney with severe hydronephrosis of upper moiety with ureterocele. Voiding cystourethrogram was done which was within normal limits. Computed

tomography of Kidney-Ureter-Bladder was done, which revealed complete duplication of left Pelvicalceal system and ureter with ectopic insertion of dilated tortuous upper moiety ureter and no excretion from upper moiety of duplicated left pelvicalceal system with normal functioning of lower moiety. Cystoscopy revealed left ureterocele. In view of this upper pole nephroureterectomy was planned.

2.1 Intraoperative steps in left upper pole heminephrectomy

Left subcostal incision was preferred. The upper pole ureter was dilated and tortuous. It was identified at the lower pole of the kidney. It was separated carefully from the lower pole ureter. The upper pole ureter was passed beneath the hilar renal vessels and retracted upward. Small feeding vessels to the upper pole are individually ligated and divided. The capsule of the upper pole was bluntly stripped away. Vascular control is achieved by temporary clamping of the lower pole vessels. Individual vessels are identified and ligated during this part of the procedure. The parenchyma of the lower pole was approximated at the site of removal of the upper pole with the use of broad mattress sutures. The redundant

capsule was then brought over the site of repair and sewn together with a running suture. Total blood loss was 150 ml. Post operative period was uneventful.

Figure 1: CT –KUB

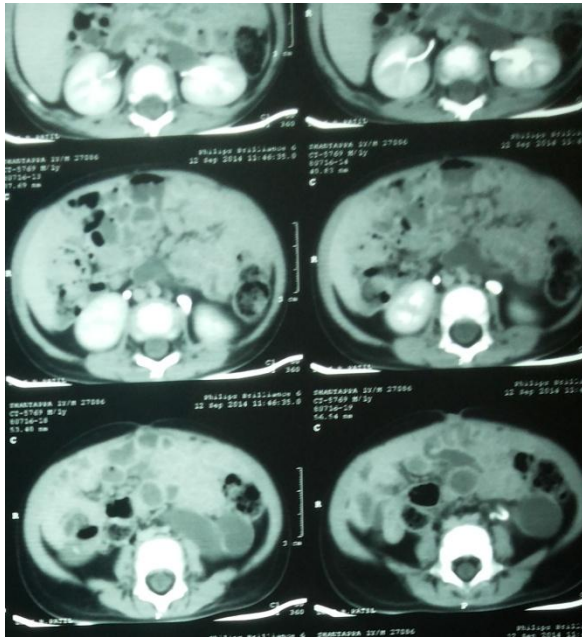


Figure showing duplication of left Pelvicaeceal system and ureter with ectopic insertion of dilated tortuous upper moiety ureter and no excretion from upper moiety of duplicated left pelvicaeceal system with normal functioning of lower moiety

Figure 2: Retrograde pyelogram showing duplex moiety.

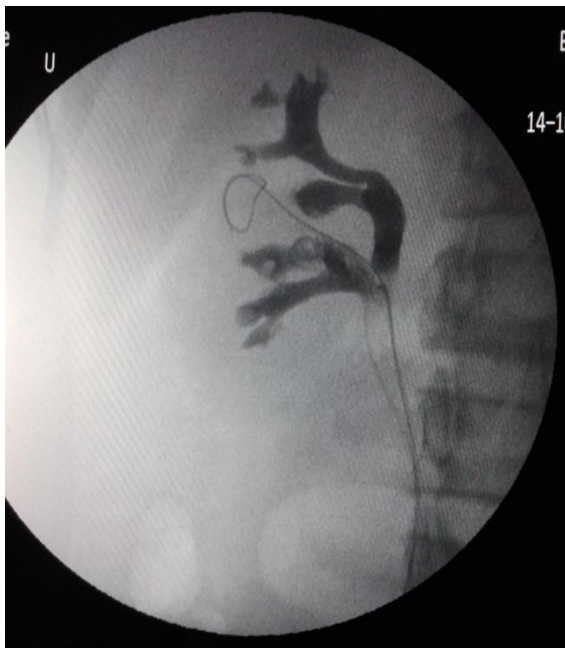


Figure 3: Intraoperative image showing dilated upper pole ureter and capsule of upper pole being stripped away

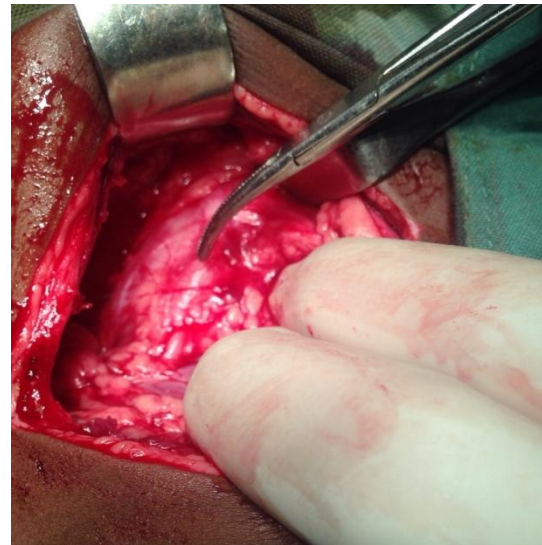
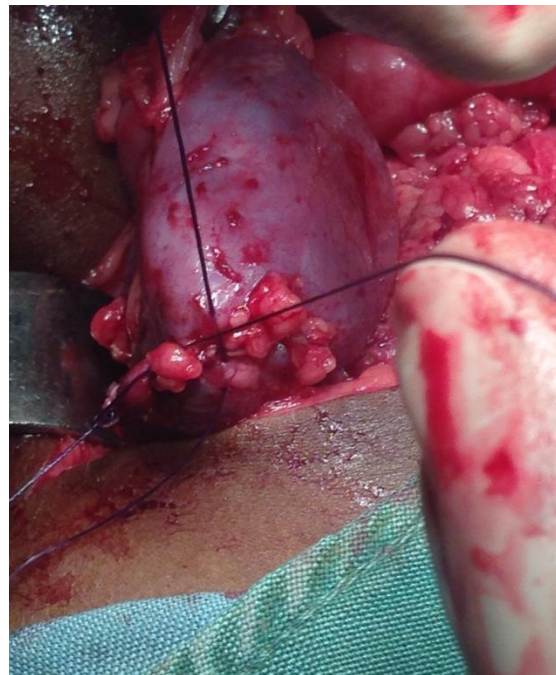

Figure 4: Intraoperative image: Individual vessels were identified and ligated.



3. Discussion

Ureterocele is classified based on development as single system or duplex system. Mandell et al proposed a classification based on features of an affected ureteral orifice[3]. American association of pediatricians has standardized terms, intravesical and ectopic according to extension into bladder, single or duplex system and in terms of orifices. Its incidence is 1:4000 children[4]. In duplex system ureterocele, upper moiety is common.

4. Conclusion

Urinary tract infection in children should be thoroughly investigated & treated. In our case the cause of urinary tract infection in an infant was secondary to ureterocele. These children require the definitive treatment. Our patient underwent left upper pole heminephrectomy. Unilateral duplex system with ureterocele is a rare entity. The goals of therapy are preservation of renal function; elimination of infection, obstruction, and reflux.

Decision making for renal parenchymal preservation is largely empirical, and there are few objective criteria to indicate how much residual function is worth preserving. Upper pole nephroureterectomy remains the stay of treatment in such patients.

References

- [1] Schluskel, R.N., Retik, A.B. Ectopic ureter, ureterocele and other anomalies of the ureter. *Campbell-Walsh Urology*. 9th edn: p.3413.
- [2] Donald S. Hill. Case studies, Prolapsed, ectopic cecoureterocele. *Journal of Diagnostic Medical Sonography*. 2004; 20 (6):436-439.
- [3] Byun E. Merguerian PA. A meta-analysis of surgical practice pattern in endoscopic management of ureteroceles. *Journal of Urology*. 2006; 176(4):1871-1877.
- [4] Chtourou M, Sallami S, Rekik H, Binous et al. Ureterocele in adults complicated with calculi: Diagnostic and Therapeutic features. Reports of 20 cases. *Prog Urol*. 2002; 12:1213-1220.