

International Journal of Biomedical and Advance Research

ISSN: 2229-3809 (Online); 2455-0558 (Print)

Journal DOI: [10.7439/ijbar](https://doi.org/10.7439/ijbar)

CODEN: IJBABN

Case Report

Hyalinizing Spindle Cell Tumour with Giant Rosettes (HSCTGR) - A sequelae neurofibromatosis

Nikhil S Shetty, Vijay P Agrawal* and Ashwin Narasimhaprasad

¹Assistant Professor, Department of General surgery, A.J Shetty Institute of Medical Sciences, Mangalore, Karnataka, India

²Assistant Professor, Department of General surgery, NKPSIMS, Nagpur, India

³Orthopaedic surgeon, Ashwini hospital, Hoskote, Bangalore, India

***Correspondence Info:**

Dr. Nikhil S Shetty,
Assistant Professor,
Dept.of General Surgery,
A.J Shetty Institute of Medical Sciences, Mangalore, Karnataka, India
E-mail: vijugunnu@gmail.com

Abstract

Generalised neurofibromatosis (von Recklinghausen's disease) 1:4000 birth is an inherited autosomal dominant disease wherein there will be multiple neuro fibromas in the body- Chromosome 17. Usual indication for excision is symptomatic neurofibroma-pain and pressure symptoms, cosmetically problematic lesion, recent increase in size, malignant transformation seen in 5 % cases. We present a very rare case- 66 year old male who underwent excision of a symptomatic neurofibroma over left popliteal joint. Three months post-operatively patient developed a fast growing tumour measuring 10 X 6 cm at the operated site. FNAC report revealed hyalinizing spindle cell tumour with giant rosettes (HSCTGR). The rarity of this tumor is demonstrated by the small number of cases available; to date, only 38 cases have been reported in the world literature.

Keywords: Neurofibromatosis, HSCTGR

1. Introduction

Hyalinizing spindle cell tumor with giant rosettes is a new, uncommon, distinctive neoplasm first reported by Lane and colleagues in 1997.[1] The ages of the patients described have ranged from 14 to 67 years (median age, 40 years); they were more often men and without symptoms. Reported lesion sizes ranged from 2.3 to 20.3 cm in diameter, with an average diameter about 6.5 cm.

Hyalinizing spindle cell tumor with giant rosettes has been described as a painless, slow-growing, well-circumscribed, solitary mass, usually located in the deep soft tissues (limbs, trunk [3] neck [6] presacral, and pararectal regions ; however, two more recent cases have been reported in the broad ligament [4] and in the lungs [5,7],

We report a very rare case of 65 year old male of generalised neurofibromatosis, who after excision of symptomatic neurofibroma over left popliteal region presented with Hyalinizing spindle cell tumour with giant rosettes (HSCTGR)

2. Case Report

A 65 year old male was admitted with a swelling measuring 10 cm X 6 cm over left popliteal region. Patient has multiple swellings all over the body. Patient also gives history of loss of weight over last two months.

Patient was diagnosed as a case of Generalised Neurofibromatosis and he underwent excision of a symptomatic neurofibroma over left popliteal region eight months back. Excision biopsy confirmed the report as Neurofibroma.

Patient developed swelling at the operated site two months following excision. It was initially a slow growing painless lump but has rapidly increased in size over the last two months to attain the present size. (**Figure 1**)

Lab findings were within the normal limit except Hb of 8gm %.FNAC of the swelling showed moderate cellularity. Cells composed of round to spindle cells in small cluster exhibiting moderate

aniso nucleosis Background shows a fibrocollagenous fragment, inflammatory cells and many RBCs. A preoperative diagnosis of Malignant Spindle cell tumour was made.

MRI showed soft tissue mass lesion with lobulated but sharp outline in subcutaneous plane extending through the fascia. Upper part of posterior tibial artery is encased by mass.

A Wide and deep excision with 3 cm margins of normal tissue all around was performed. (Figure 2,3). Histopathology revealed Hyalinizing spindle cell tumour with giant rosettes (HSCTGR) (figure 4,5)

Figure 1: Swelling with scar mark measuring 10cm x6cm over left popliteal region

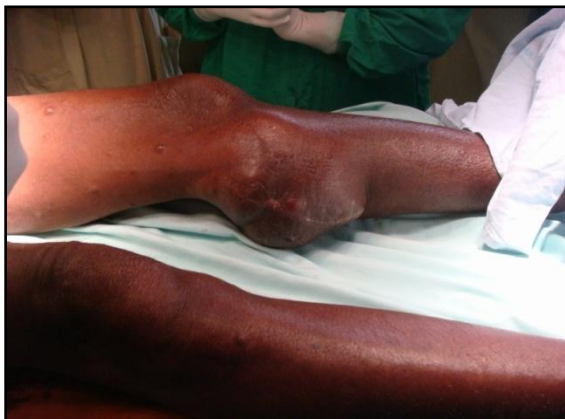

Figure 2: Wide local excision with mass being delivered out

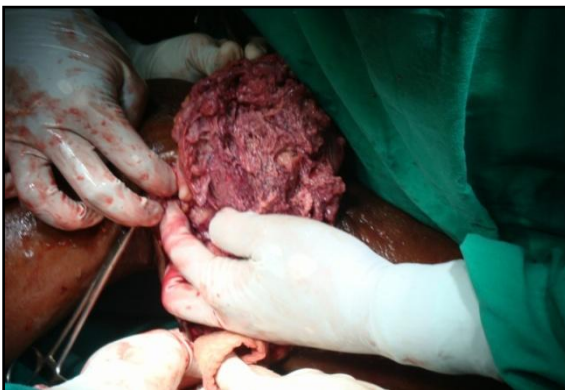

Figure 3: Excised Specimen



Figure 4: Hyalinizing Spindle cell tumour with giant rosette

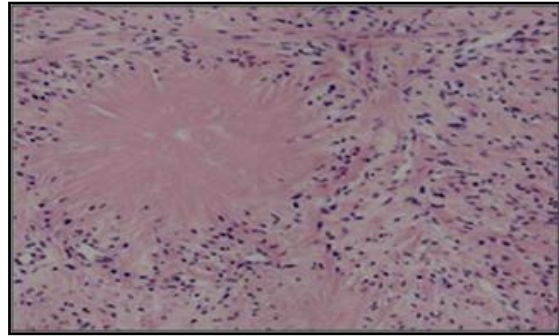
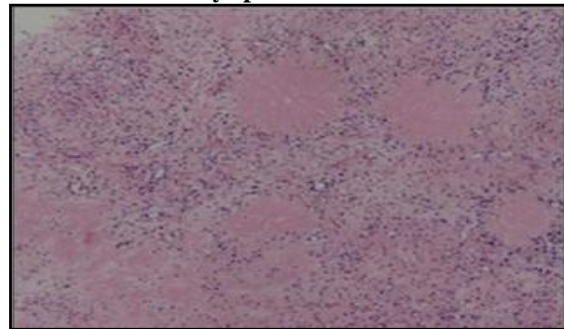


Figure 5: Several rosettes like structure separated by spindle areas



3. Discussion

Hyalinizing spindle cell tumor with giant rosettes is a recently described biphasic neoplasm of soft tissues that shares mesenchymal and neuroendocrine features. Its morphologic structure is distinctive, with the presence of hyalinized paucicellular foci that are termed rosettes.

It is a rare form of fibrosarcoma which shows considerable overlap with low grade fibromyxoid sarcoma and is now regarded as a variant of the latter tumor.[2,7] It generally presents in younger adults and the limbs and trunk are sites of predilection.

The histology is characteristic and typified by a somewhat bland spindled cell proliferation with fascicular and whorling growth patterns. There is generally a well-developed vasculature. Mitotic activity is very sparse. The tumor shows varying collagenous and myxoid areas. Large hyalinized, collagenous rosettes surrounded by tumor cells are the diagnostic feature.

The spindled cells express vimentin and in a small percentage of cases SMA.[8] The rosettes are composed of basement membrane material including type IV collagen, laminin and fibronectin. The tumor is biologically generally low grade with metastasis and death rates of 6% and 2% respectively. Wide local excision is the treatment of choice. Differential diagnosis may include conventional fibrosarcoma, myxofibrosarcoma and diffuse neurofibroma.

References

- [1] Lane KL, Shannon RJ, Weiss SW. Hyalinizing spindle cell tumor with giant rosettes. A distinctive tumor closely resembling low-grade fibromyxoid sarcoma. *Am J Surg Pathol* 1997; 21: 1481-8.
- [2] Evans HL. Low grade fibromyxoid sarcoma. A report of 12 cases. *Am J Surg Pathol* 1993; 17: 595-600.
- [3] Woodruff JM, Antonescu CR, Erlandson RA, Boland PJ. Low grade fibrosarcoma with palisaded granuloma-like bodies (giant rosettes). Report of a case that metastasized. *Am J Surg Pathol* 1999; 23: 1423-8.
- [4] O'Sullivan MJ, Sirgi KE, Dehner LP. Low-grade fibrosarcoma (hyalinizing spindle cell tumor with giant rosettes) with pulmonary metastases at presentation: case report and review of the literature. *Int J Surg Pathol* 2002; 10: 211-6.
- [5] Magro G, Fraggetta F, Manusia M, Mingrino A. Hyalinizing spindle cell tumor with giant rosettes. A previously undescribed lesion of the lung. *Am J Surg Pathol* 1998; 22: 1431-3.
- [6] Weiss SW, Goldblum JR. Enzinger and Weiss's soft tissue tumors. 4th ed. St. Louis: Mosby, 2001; 431-5.
- [7] Folpe AL, Lane KL, Paull G, Weiss SW. Low-grade fibromyxoid sarcoma and hyalinizing spindle cell tumor with giant rosettes. *Am J Surg Pathol* 2000; 24: 1353-60.
- [8] Nielsen GP, Selig MK, O'Connell JX, Keel SB, Dickersin GR, Rosenberg AE. Hyalinizing spindle cell tumor with giant rosettes. A report of three cases with ultrastructural analysis. *Am J Surg Pathol*. 1999 Oct; 23(10):1227-32.