

International Journal of Biomedical and Advance Research

ISSN: 2229-3809 (Online); 2455-0558 (Print)

Journal DOI: [10.7439/ijbar](https://doi.org/10.7439/ijbar)

CODEN: IJBABN

Case Report

Retroperitoneal sarcoma with femoral and inguinal herniation: A rare case report

**Kumble Ananthprabhu, Dilber Pareed. K^{*}, Deepika Patil, Sachin Sreedharan
And Abdul Majeed***Department of General Surgery, Yenepoya University(Deemed University), Derlakkatte,Mangalore, Karnataka, India****Correspondence Info:**

Dr. K DilberPareed,
Department of General Surgery,
Yenepoya University (Deemed University),
Derlakkatte, Mangalore, Karnataka, India
E-mail: dilber.dr@gmail.com

Abstract

Liposarcoma is a malignant tumor that arises in fat cells in deep soft tissue, such as that inside the thigh or in the retroperitoneum. They are typically large bulky tumors which tend to have multiple smaller satellites extending beyond the main confines of the tumor. It accounts for approximately 20% of all mesenchymal malignancies. These sarcoma are remarkable because of their frequently large size. We report a case of a large well-differentiated retroperitoneal liposarcoma that weighted 9.5 kilograms with inguinal and femoral herniation of the same mass. The patient underwent surgery and is planned for adjuvant radiotherapy.

Keywords: Liposarcoma, Retroperitoneal Space, Inguinal Hernia, Femoral Hernia**1.Introduction**

Liposarcoma is a malignant tumor of mesenchymal origin in which the bulk of tumor differentiates into adipose tissue. The major sites of liposarcoma are the extremities, retroperitoneum and inguinal region. Liposarcomas are remarkable because of their frequently large size and they are among the largest tumors.[7] Liposarcoma is regarded as a tumor in adult, and is rarely found in areas in which most of body fat is usually stored. Complete resection is mandatory for cure. Histological subtypes, not location, is predictive of long-term survival. Considering currently available data, the most logical classification of liposarcoma is into three main groups: (1) well-differentiated liposarcoma (including adipocytic, sclerosing, inflammatory, spindle-cell, and dedifferentiated variants), characterized by ring or long markers chromosomes derived from the long arm of chromosome 12; (2) myxoid and round cell (poorly differentiated myxoid) liposarcoma, characterized in most cases by a reciprocal translocation t(12;16)(q13;p11); and (3) pleomorphic liposarcoma, characterized by complex

karyotypes.[1][2] We report a case of a well-differentiated liposarcoma that weighted 9.5 Kg.

2. Case Report

A 48- year-old man presented with progressive enlargement of abdomen since past 2 years. There was no history of abdominal pain or associated bowel symptoms for the past 1¼ years. Since patient had complaints of only abdominal distension, he didn't show to any hospital until 2 weeks prior admission, when he had difficulty in taking food due to the fullness he experienced. He had moderate weight loss, but the amount of it is unknown. He has good appetite. He also had increased frequency of micturition since few weeks. His Karnofsky score was 80.

On examination, single Mass was palpable in the abdomen occupying Right lumbar, Right iliac, umbilical, hypogastric and epigastric region of approximate size.36 x 28 cm which was nodular, variable in consistency (firm and soft areas), mobile, mostly horizontal and with restricted vertical

mobility. There was no ballot ability. Further he also had right femoral and complete right side inguinal hernia. Both were not reducible.

Ultrasound abdomen showed it as a large mixed echoic lesion in the midline extending from the epigastric region to the pelvis. Lesion was compressing the urinary bladder and right ureter causing moderate hydronephrosis. Lesion was also causing displacement of the adjacent bowel loops. CT scan showed features suggestive of fat containing malignant neoplasm-Liposarcoma. But to our surprise USG guided trucut biopsy report came as fibrolipoma. Repeat biopsy revealed the same report. Peripheral blood tests revealed anemia. Chest X-ray was normal.

After anaemia correction, patient was taken up for surgery under General Anesthesia. Laparotomy was done. The tumor had moderate adhesions, but gross invasion of tumor to adjacent organs was not seen. The tumor was encapsulated and lobulated. The origin of the tumor was from retroperitoneum, and by meticulous dissection it was separated from aorta, kidneys, and ureters and abdominal part of the mass was removed en bloc.

The dimension of tumor was 38×23×21 cm and its weight about 9.5 kg. There was no gross tumor residual left in the abdomen. The abdominal wall has been stretched excessively and due to decreased intra-abdominal pressure. Further the content of the complete right inguinal hernia as well as the right femoral hernia was the same mass which was herniating through the deep inguinal ring and so was dealt separately through 2 different incisions. The pathological report was well-differentiated liposarcoma. Immunohistochemistry showed lipoblasts were S 100 positive. Patient was asked to come for follow up for further management (Radiotherapy).

Figure 1: Markings showing mass size

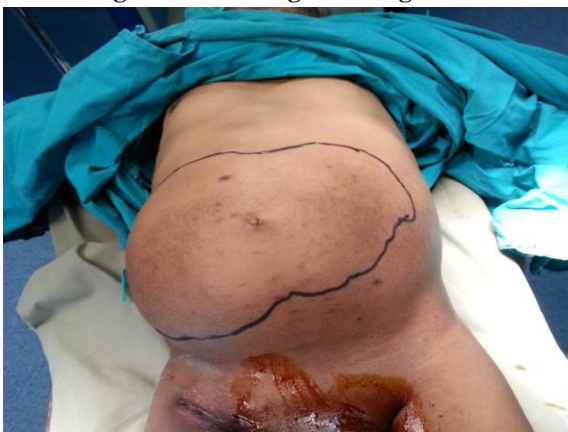

Figure 2: CT Abdomen showing the huge mass

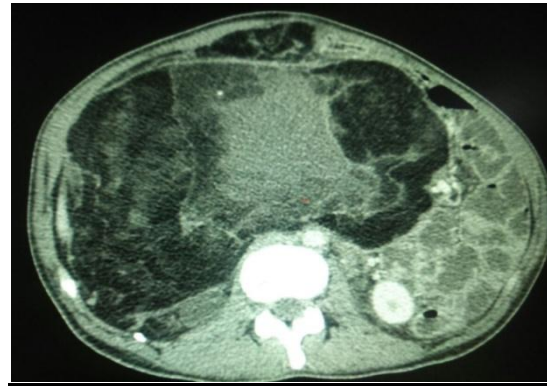


Figure 3: Right Femoral hernia which wasthe same mass abdomen herniating

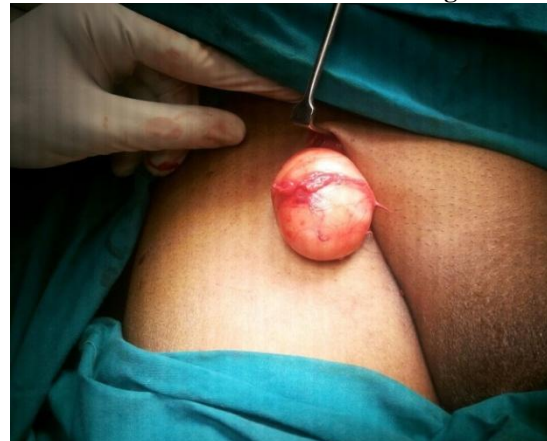
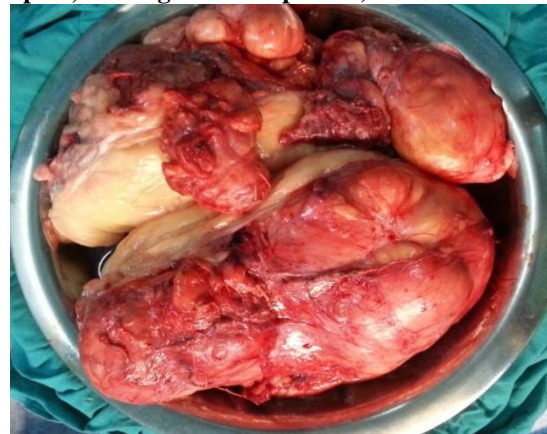
Figure 4: Complete mass (Mass abdomen, femoral part, and inguinal component) after excision.



3. Discussion

Virchow first described liposarcoma in the 1860s. Liposarcoma normally appears as a slowly enlarging, painless, nonulcerated submucosal mass in a middle-aged person, but some lesions grow rapidly and become ulcerated early. In the published literatures, bigger ones like 18 kg, 32 kg and 42 kg liposarcoma have been reported.[10][11][12]

The anatomical distribution of liposarcoma appears to be partly related to the histologic type. Well-differentiated liposarcoma tends to occur in deep soft tissues of both the limbs and the

retroperitoneum. Myxoid and/or round-cell liposarcomas and pleomorphic liposarcomas have a striking predilection for the limbs, and dedifferentiated liposarcoma occurs predominantly in the retroperitoneum. Although any liposarcoma subtype occasionally arises in the subcutaneous tissue, involvement of the dermis appears to be exceedingly rare.

3.1 Radiographic features

3.1.1 CT

Liposarcomas have three CT patterns based on amount and distribution of fat in tumour:

- **Solid:** attenuation over +20 HU
- **Mixed:** areas of less than -20 HU and areas of over +20 HU
- **Pseudocystic:** homogenous density between -20 and +20 HU

CT findings favouring a liposarcoma from a lipoma include: inhomogeneous attenuation, with evidence of significant amounts of soft-tissue within the fatty mass, poor definition of adjacent structures, evidence of infiltration or invasion of mediastinal structures.

3.1.2 MRI

MRI appearance, as with CT, varies depending on the grade and amount of fatty tissue. Low grade lesions (atypical lipomas) are almost entirely fat signal with however thick septae, enhancement or evidence of local invasion. These features are used to distinguish these from simple lipomas. The higher grade lesions are often devoid of macroscopic fat and have appearances similar to other sarcomas.

3.3 Treatment and prognosis

Treatment varies with location and grade. Basis of treatment involves complete surgical resection.[3][6] Radiation therapy may be a valuable adjunct to surgery, especially in those of the myxoid variant. Occasionally neoadjuvant doxorubicin-based chemotherapy and/or external beam radiation therapy has utility in reducing the size of the tumor in patients with large lesions or those adjacent to vital structures. The use of chemotherapy in liposarcomas remains experimental.[9]

Liposarcoma prognosis is reported based on disease subtype.[4] Five-year disease specific survival rates (chances of not dying from cancer-related causes) are as follows: 100% in well-differentiated liposarcoma, 88% in myxoid liposarcoma, and 56% in pleomorphic liposarcoma. Ten-year survival rates are 87% in well-differentiated liposarcoma, 76% in myxoid liposarcoma and 39% in pleomorphic liposarcoma. However, the site of

disease has a strong effect on prognosis of well-differentiated and de-differentiated liposarcoma.

Authors' Contributions

All authors have carried out the study and took part in writing the draft of manuscript. All authors read and approved the final manuscript.

Conflict of Interests

Authors have no conflict of interests.

References

- [1] Dei Tos AP. "Liposarcoma: new entities and evolving concepts". *Ann Diagn Pathol* 2000; 4(4): 252–66. doi:10.1053/adpa.2000.8133
- [2] Fernandez-Ruiz M, Rodriguez-Gil Y, Guerra-Vales JM, Manrique-Municio A, Moreno-Gonzalez E, Colina Ruizdelgado F. Primary retroperitoneal liposarcoma: clinical and histological analysis of ten cases. *Gastroenterol Hepatol*. 2010; 33(5):370–6.
- [3] Hassan I, Park SZ, Donohue JH, Nagorney DM, Kay PA, Nasciemento AG, et al. Operative management of primary retroperitoneal sarcomas: a reappraisal of an institutional experience. *Ann Surg*. 2004; 239(2):244–50.
- [4] Perez EA, Gutierrez JC, Moffat FL, Jr, Franceschi D, Livingstone AS, Spector SA, et al. Retroperitoneal and truncal sarcomas: prognosis depends upon type not location. *Ann Surg Oncol*. 2007; 14(3):1114–22.
- [5] McCallum OJ, Burke JJ, Childs AJ, Ferro A, Gallup DG. Retroperitoneal liposarcoma weighing over one hundred pounds with review of the literature. *Gynecol Oncol*. 2006; 103(3):1152–4.
- [6] Hashimoto Y, Hatakeyama S, Tachiwada T, Yoneyama T, Koie T, Kamimura N, et al. Surgical treatment of a giant liposarcoma in a Japanese man. *Adv Urol*. 2010; 2010:943073.
- [7] Herrera-Gomez A, Ortega-Gutierrez C, Betancourt AM, Luna-Ortiz K. Giant retroperitoneal liposarcoma. *World J Surg Oncol*. 2008; 6:115.
- [8] Lewis JJ, Leung D, Woodruff JM, Brennan MF. Retroperitoneal soft-tissue sarcoma: analysis of 500 patients treated and followed at a single institution. *Ann Surg*. 1998; 228(3):355–65
- [9] Mohanty R, Bhat MN, Chawla SC. Retroperitoneal atypical lipomatous tumour--a case report. *Indian J Pathol Microbiol*. 2000; 43(2):157–60.
- [10] Antinori A, Antonacci V, Magistrelli P. Giant retroperitoneal liposarcoma. *Am J Surg*. 2002; 184(1):56–7.
- [11] Goertz RS, Lenfers BH, Goertz GH. Huge liposarcoma of the left retroperitoneum. *Am J Surg*. 2009; 197(6):e59–e60.
- [12] Bradley JC, Caplan R. Giant retroperitoneal sarcoma: a case report and review of the management of retroperitoneal sarcomas. *Am Surg*. 2002; 68(1):52–6.