

International Journal of Biomedical and Advance Research

ISSN: 2229-3809 (Online); 2455-0558 (Print)

Journal DOI: [10.7439/ijbar](https://doi.org/10.7439/ijbar)

CODEN: IJBABN

Case Report

Abnormal musculotendinous slip from Biceps Brachii to Pronator Teres: A Case Report

Soumitra Trivedi*, Sinha MB, Sharma DK, Rathore M, Siddiqui AU

Department of Anatomy, All India Institute of Medical Sciences, Raipur

***Correspondence Info:**

Dr. Soumitra Trivedi,
Assistant Professor,
Department of Anatomy,
All India Institute of Medical Sciences,
Raipur, (C.G.) – 492099, India.
E-mail: dr.trivedi.aiims@gmail.com

Abstract

Variations of upper limb muscles are quite commonly seen during dissection. Biceps Brachii take an edge on this, as it commonly has two or more than two sites of origin and insertion, where mode of insertion being both aponeurotic as well as tendinous. In present study, apart from common modes of insertion, an additional musculotendinous slip was seen running from the medial side of the muscle belly of Biceps Brachii to Pronator Teres and Flexor Carpi Radialis deep to the aponeurosis. The functional aspect of such insertion is also questionable as Biceps brachii being a supinator is gaining attachment to a Pronator Muscle. Presence of such abnormal musculotendinous tissue can pose a difficult situation during surgical procedures in and around cubital fossa and can also be a cause of nerve entrapment syndromes. Additional muscular slip can lead to compression of neurovascular structure around that area.

Keywords: Biceps Brachii, Pronator Teres, Variation, Compression syndrome.

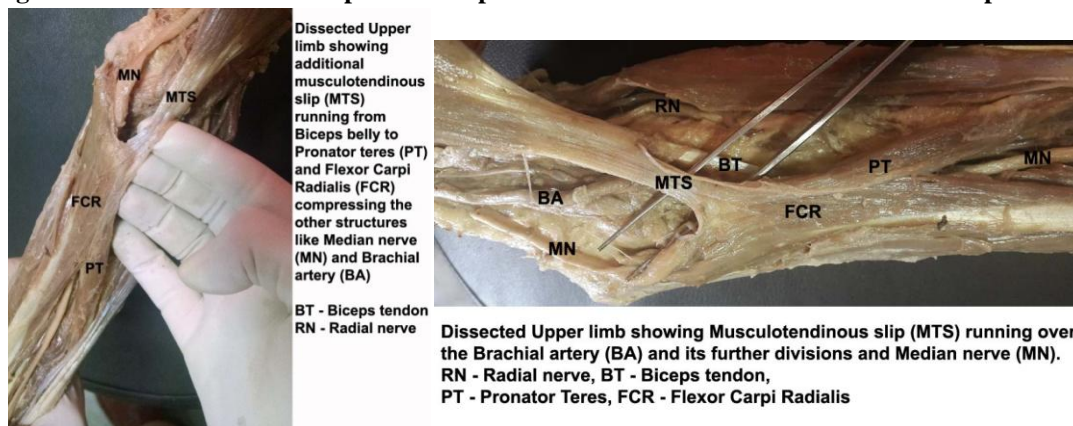
1.Introduction

Variation encountered during dissection in the upper limb are quite common, they can be vascular, neural or muscular. Muscular variation is most commonly seen in Biceps Brachii muscle as it has two heads, long and short, originating from Supraglenoid tubercle and lateral side of the top of Coracoid process of Scapula respectively and two modes of insertion, tendinous insertion going to posterior surface of Radial Tuberosity and aponeurotic insertion going to Posterior border of ulna after mixing with deep fascia of the forearm[1]. In addition to this, supernumerary heads of origin of Biceps have been described which can three or four in number[2]. Sufficient literature is available on origin of Biceps but the variability of its insertion has not been thoroughly explored[3]. Literature has been documented regarding additional head of pronator teres arising from the tendon of the brachialis muscle or from tendon of the biceps brachii muscle and some other sites[4]. Additional heads of Pronator Teres and

Flexor Carpi Radialis have been described arising from Bicipital Aponeurosis[5]. Cases of the pronator syndrome caused by compression of the median nerve by a fibrous band as the nerve passed through the humeral head of origin of pronator teres has been reported[6].

2.Case Report

During the routine dissection class of the undergraduate students it was noticed that the mode of insertion of Bicipital aponeurosis was not as traditionally described in the books. The tendinous head was going normally to the Posterior part of Radial tuberosity but the aponeurotic part was totally replaced by a musculotendinous slip which was extending from the medial side of biceps belly and was gaining attachment on to the Pronator Teres as well as Flexor Carpi Radialis. Median Nerve along with Brachial Artery and its division into Radial and Ulnar Arteries were seen lying deep to the slip.

Figure 1: Musculotendinous slip from Biceps Brachii to Pronator Teres and Flexor Carpi Ulnaris

3. Discussion

Morphologically, Biceps Brachii is considered most variable muscle of the human body, as it can present with supernumerary heads of origin. At the sites of insertion also, although rare, but variations are encountered. Embryologically, the upper limb develops from confined somites that migrate to form the limb bud. These somites under higher molecular regulation lead to muscle formation by differential growth and apoptosis. Usually the variations of the muscle arise due to the unevenness in the expression of genes and process, thus resulting in absence, presence or abnormal orientation of the muscle or its part[7].

Due to such variations in biceps anatomy, Surgeon might get confused while performing any operative procedure on the arm that may result in to iatrogenic injuries[8]. The bony fragments subsequent to fractures might show unusual displacement due to additional head of the muscle or its aponeurosis which might be challenging for an orthopedician[9]. Compression of neurovascular structures because of close relationship of such slips to the brachial artery and median nerve may lead to ischemic symptoms, paraesthesia or weakness in muscles. Therefore, surgeons should be aware of these anatomical variations of biceps brachii when dealing with the clinical syndromes[10]. New imaging techniques, such as computed tomography and magnetic resonance imaging should be inculcated more for the timely diagnosis of anatomical variations and abnormalities of the muscles of the upper limb. No relevant matter was available for understanding the functional significance of this abnormal communication that existed between muscles causing supination with a muscle causing pronation. Normally Bicipital Aponeurosis goes to posterior border of ulna after mixing with the deep

fascia; any pull by this aponeurosis will assist in supination. But if such aponeurosis is replaced by a musculotendinous slip and is gaining attachment to pronator muscle, may lead to some functional differences.

4. Conclusion

Knowledge of the sites and modes of insertion of Biceps Brachii is equally important as its variation in the origin, especially for preoperative diagnosis during any surgical procedure to be attempted in the concerned area. CT and MRI have always proved to be significant in diagnosis of such conditions. Electromyographic studies can be done to understand for any functional deviations caused by such additional slip. Thus, a clinician should be aware of any such musculotendinous slip that might exist and lead to variety of clinical symptoms which can be either due unusual displacement of fracture segments of in the form of compression syndromes.

References

- [1] Standing S. Gray's Anatomy. The Anatomical Basis of Clinical Practice. 40th ed. Edinburg, Churchill Livingstone-Elsevier.2008: 825-26
- [2] Tesut L, E. Tratado de Anatomia Humana. Barcelona; *Salvat*, 1902: 1022
- [3] Eames MHA, Bain GI, Fogg QA, Van Riet RP. Distal Biceps tendon anatomy: a cadaveric study. *J Bone Joint Surg Am* 2007; 89 (5): 1044-49.
- [4] Nebot CJ, Reina-DTF, Pérez B. Accessory fasciculi of the human pronator teres muscle: incidence, morphological characteristics and relation to the median nerve. *Ann Anat.* 1994 Jun; 176(3):223-7
- [5] Bhat MR, Kulkarni V, Gupta C. Additional muscle slips from the Bicipital aponeurosis and a

- long communicating branch between the musculocutaneous and the median nerves. *International journal of Anatomical Variations*. 2012 (5): 41-43
- [6] Tulwa N, Limb D, Brown RF. Median nerve compression within the humeral head of pronator teres. *J Hand Surg Br*. 1994 Dec; 19(6):709-10.
- [7] Mooney EK, Loh C. Hand Embryology Gross Morphologic Overview of Upper Limb Development. *Source* - <http://emedicine.medscape.com/article/1287982-overview>.
- [8] Ramakrishna A and Chakravarthi KK. A study on morphology of the biceps brachii muscle. *NUJHS* 2012; 2(3): 2-5.
- [9] Daimi SR, Siddiqui AU, Wabale RN, Gandhi KR. Additional tendinous insertion of Biceps Brachii: A Case Report. *Pravara Med Rev* 2010; 2(1): 16-18
- [10] Warner JJ, Paletta GA, Warren RF. Accessory head of the biceps brachii. Case report demonstrating clinical relevance. *Clin Orthop Relat Res* 1992; 280: 179-181.