

International Journal of Biomedical and Advance Research

ISSN: 2229-3809 (Online); 2455-0558 (Print)

Journal DOI: [10.7439/ijbar](https://doi.org/10.7439/ijbar)

CODEN: IJBABN

Case Report**Hepatic Metastasis of Omental Hemangiopericytoma: Case report****Rajendra Prasad Bugalia^{*1}, Anuradha Salvi², Dhananjay Saxena¹, Prashant Garg¹,
Raj Kamal Jenaw¹, Vipul Agarwal¹ and Jeevan Kankaria¹**¹Department of General Surgery, SMS Medical College, Jaipur, Rajasthan India²Department of obstetrics and Gynaecology, SMS Medical College, Jaipur, Rajasthan India***Correspondence Info:**

Dr. Rajendra Prasad Bugalia

Flat no. 4 Zenana Hospital Campus Chandpole

Jaipur Rajasthan 302016 India

E-mail: drprbugalia@gmail.com**Abstract**

Hemangiopericytoma (HPC) is a rare tumor that arises from the pericytes of Zimmermann. HPCs have a characteristic clinical feature the rate of recurrence which is as high as 52% of cases mostly in the lungs, liver, and regional lymph nodes and which necessitates long-term follow-up after resection of the primary tumor. Complete surgical removal is the treatment of choice for primary tumor local recurrence and solitary metastasis. The liver is an unusual location to the primary HPC but has been described as one of the most common site of distal metastases besides the bones and lungs. We present a case of a 55 year old man who was known case of an isolated omental HPC treated with excision of the omental mass 6 year back which recurred solely to the liver. The tumor occupied almost the entire left lobe with 9 x 7x 8 cm of diameter. The patient was submitted to uneventful uncomplicated left hepatectomy. In cases of inoperable recurrence or metastasis palliative chemotherapy is indicated though there is currently no approved chemotherapy regimen. Even though HPC is a well known neoplasm its incidence is very low. This article describes a case and addresses questions regarding diagnosis prognosis and treatment of this rare event.

Keywords: Hemangiopericytoma, Liver, Recurrence, Surgery**1.Introduction**

Hemangiopericytoma is a stromal tumor originated in the pericytes of Zimmermann localized periferically to capillaries and post capillary venules responsible for the contractility of these vessels. The tumor commonly occurs in lower extremities (34.4%) pelvic fossa retroperitoneum(24.5) head and neck, trunk and upper extremities.[1] Hemangiopericytomas (HPCs) are rare neoplasms which account for approximately 1% of primary vascular tumors. Patients with hemangiopericytoma can experience either early or late local recurrences or distal haematogenous metastases. The most frequent sites of metastases are lung, liver and bone. It was first described by Stout and Murray in 1942 and there are approximately 1000 cases in the literature[2]. Its affect mostly 5th decade of life in both gender. There is also an infantile form with better prognosis and reports of spontaneous

regressions of the primary lesion[3]. This neoplasia is known to have a slow almost painless growth and tends to be diagnosed only when has become a big mass. Computed tomography (CT) Magnetic resonance imaging (MRI) and angiography are classically considered the diagnostic modalities of choice for preoperative evaluation and surgical planning. Recently contrast enhanced MRI has emerged as a valuable non-invasive technique which provides a rich analysis of the regional vascular properties of a tumour. Among sarcoma the most distinctive and consistent feature of hemangiopericytoma is its hypervascularity. The consensus of the literature is to treat all resectable tumour lesions including local recurrences and a solitary metastasis with wide excision. Increased sensitivity of new diagnostic imaging modalities in the detection and characterization of liver metastases

has created a need for detailed understanding of the pathological-radiological relationship of each type of tumour. In spite of its prolonged course and slow growth rate it has a high recurrence rate (32% - 60%) characteristically as a distant metastasis and a long time after the primary resection[4]. The liver is considered to be only the third most common site of metastasis generally due to primary pelvic or retroperitoneal primaries[4]. The prognosis for these patients is very variable and less than 50% are disease free at 5 years. Recurrences can develop following an extended disease free interval with nearly 50% of recurrences occurring at 3 or more years after diagnosis and reported cases relapsing after 20 years. Radical surgery remains the mainstay of therapy. Therefore, the early detection of locoregional and distant recurrence can play an effective role in the prognosis of these patients. A careful long-term follow up is mandatory for these patients.

2. Case Report

We assisted a 55 year old male a known case of omental hemangiopericytoma previously operated 6 year back who came with history of abdominal lump since 6 month and fainting 2 episodes over past 1 week. On examination patient vitals were normal. Per abdominal examination revealed the midline scar mark of previous surgery. Lump was 8×10 cm in epigastric region spherical in shape, hard consistency, smooth surface, well defined margins and mobile with respiration. Liver span was 18 cm. There was no history of pain abdomen, vomiting, hematemesis, melena, weight loss, anorexia and jaundice. History of fainting 2 episodes associated with dizziness which recovered on oral sugar intake; Similar to episodes prior to previous operation.

Patient was known case of omental hemangiopericytoma operated in 2008, 8×8×9 cm omental mass excised (Figure 1). Histopathology shows hemangiopericytoma of omental mass.

All routine blood investigation was within normal limit. Ultrasound showed a solid hypoechoic mass 8×8 cm in epigastric region extending to left hypochondrium suggestive of left lobe hepatic mass. CECT abdomen showed well defined heterogenous density space occupying lesion in left lobe liver segment II and III, around 9×7×8 cm showing irregular nodular enhancement on post contrast scan with multiple necrotic foci suggestive of primary or metastatic hepatic mass (Figure 2).

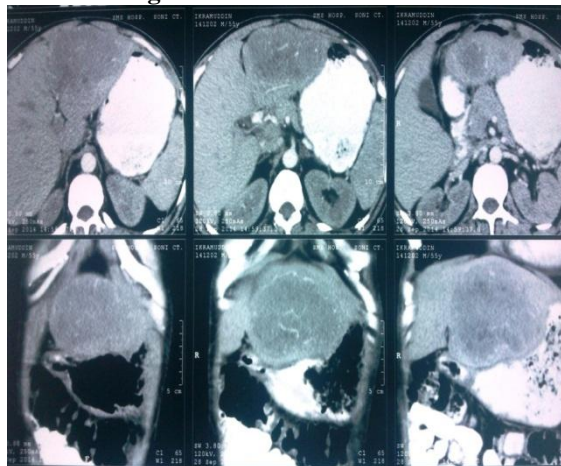
Exploratory laparotomy was planned. Per operative finding showed large mass about 10×10 cm

present in left lobe of liver, right lobe of liver and omentum was normal, no peritoneal and visceral metastasis was present. Thus left hepatectomy was done (Figure 3-5). Post operative period was uneventful and patient discharged on day 7 with stable vitals. On follow up histopathological report of multiple sections from the growth showed multiple vessels surrounded by spindle cells, vessels containing RBCs overall features suggestive of hemangiopericytoma. Patient referred to medical oncology department for further management.

Figure 1: Intra operative picture of Omental mass which was excise 6 year back.

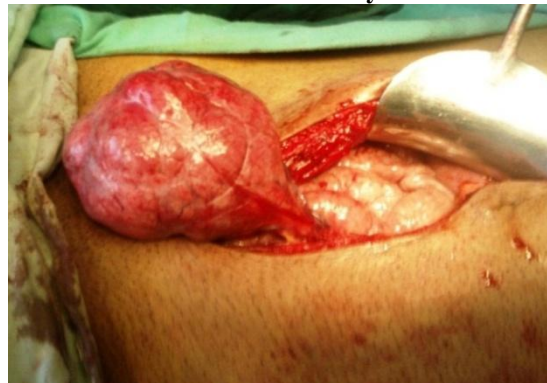

Figure 2: CECT of abdomen



CECT abdomen showing a ill defined heterogenous density space occupying lesion of left lobe liver segment II and III size 9×6×7 cm enhancement on post contrast scan with multiple necrotic foci suggestive of primary or metastatic mass.

Figure 3: Intraoperative picture of hepatic mass occupying about whole of the left lobe.

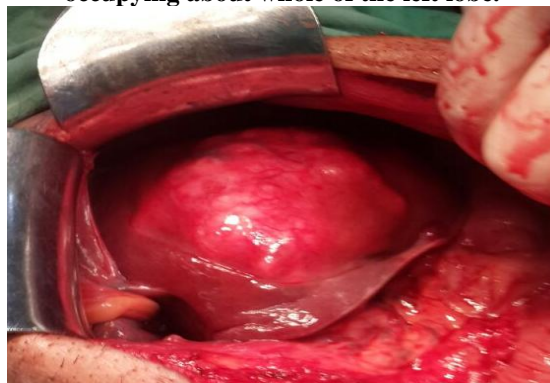


Figure 4: Intraoperative picture after left hepatectomy

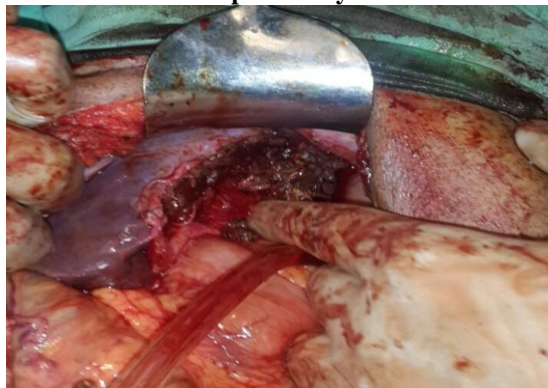
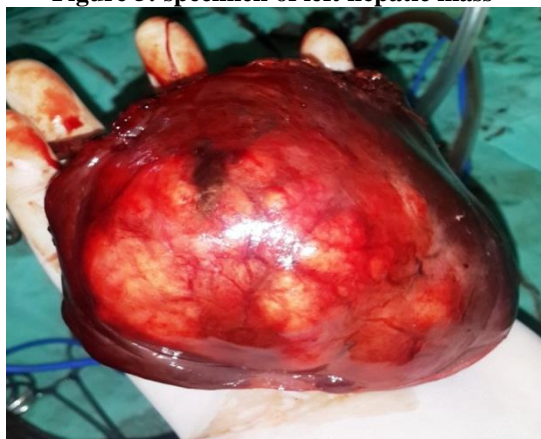
Figure 5: specimen of left hepatic mass



3. Discussion

Hemangiopericytoma is an indolent slow growing tumor in its classical presentation, with a high recurrence rate. As originated in the capillary pericytes it can arise in any part of the body but the liver is seldom a primary location. In spite of it the liver remains the third commonest metastatic site mostly in cases where the primary tumor was located in the pelvis or retroperitoneum.[5] HPCs have some characteristic clinical features. One of these features is the rate of recurrence, which is as high as 52% of cases mostly in the lungs, liver, and regional lymph nodes and which necessitates long-term follow-up after resection of the primary tumor. Other interesting features are the various para-neoplastic symptoms, including hypoglycemia and hypertension which accompany this neoplasm because the tumor can secrete insulin-like substances and hyper-utilize glucose.[6] A review of the literature revealed that the size of a tumor causing hypoglycemic symptoms ranged from 12 to 27 cm. In our patient the size of the primary tumor was $9 \times 8 \times 7$ cm. There is clearly a bigger recurrence rate in patients with tumors sited in the abdominal pelvis or the head and neck than in those located in the limbs[4].

Diagnosis is generally late and confirmed with immunohistochemistry. Fine needle aspiration

(FNA) should not be accomplished for it won't obtain sufficient tissue for the diagnosis. The indicated procedure is the cut biopsy and careful hemostasis. In spite of the certain diagnosis can only be assured with immunohistochemistry there are some radiological characteristics that raise the suspicion of HPC these are intense peripheral hypervascularization with serpiginous vessels. MRI patterns are isointensity in T1 and hyperintensity in T2 both in the periphery due to the vascularity and in the core due to central necrosis that may occur in big masses. However these characteristics are inespecific and also commonly seen in the angiosarcomas[7]. There are two more common presentations of liver metastasis: either a single slightly painful voluminous mass or multiple nodules, being the former the most frequent. The consensus of the literature is to treat all resectable tumour lesions including local recurrences and a solitary metastasis with wide excision. Most of the time resections tend to be large and raise the concern with the remnant liver volume. There are other therapeutic options that may increase resectability. The first one is arterial embolisation through Seldinger technique. There are well succeeded cases of hepatic artery embolisation which reduced tumor size allowing curative resection[8]. Portal vein embolisation induces vicarious hypertrophy of the future liver remnant permitting resection in primarily unresectable patients due to the small liver remnant expected. Other reported forms of treatment are radiofrequency ablation (RFA) for small single centrally located lesions in patients who cannot stand surgery or have already been operated[9]. Tumor resection is the only curative treatment option for this disease. Recurrence is high even after long periods of follow up.

Most authors defend resection when possible for recurrent disease because long survivals can be expected due to the indolent growth. Other forms of treatment such as radiation or chemotherapy still play uncertain roles. There are various reports of favorable outcomes with adjuvant radiation therapy in head and neck intracranial and pelvic tumors. In regard to adjuvant chemotherapy most studies have shown unfavorable results. The most distinctive and consistent characteristic of HPC among sarcomas is its hypervascularity providing the rationale for using anti-angiogenesis drugs such as endostatin and ginsenoside. HPC also expresses both the platelet-derived growth factor and the vascular endothelial growth factor receptors.[10] Human endostatin specifically inhibits the proliferation and migration of capillary endothelial cells *in vitro* and can induce apoptosis. Previous studies have indicated that

endostatin affects a network of potentially intersecting pathways that are important in the angiogenic phenotype. Many studies have shown that ginsenoside can inhibit proliferation, infiltration, and metastasis of tumor cells.[10]

There are no established criteria for the follow up of these patients. World literature consensus is that these patients need a long term maybe lifelong follow up due to the high risk of recurrence. In our case the patient experienced recurrence 6 years after surgery. It is suggested the use of yearly positron emission scans to be a reasonable alternative in spite of the high cost. One of the most unfavorable prognostic factors is tumor size greater than 5cm in diameter. Another factor was the presence of central tumor necrosis in the CT scan. However there is no general agreement in the number of mitoses is mentioned as the main prognostic factor being more than 4 mitoses/10 HPF as an indication of shorter disease free and overall survival.

4. Conclusion

Because HPC is a rare entity and liver metastases of HPC are even rarer it is difficult to standardize diagnostic, treatment and follow up protocols. Resection must always be attempted even though extended resections may necessary because it remains the only chance of cure.

References

- [1] Matsuda S, Usui M, Sakurai H, et al. Insulin-like growth factor II-producing intra-abdominal HPC associated with hypoglycemia. *J Gastroenterol* 2001; 36: 851-855.
- [2] Stout AP, Murray MR: Hemangiopericytoma: a vascular tumor featuring zimmermann's pericytes. *Ann Surg* 1942, 116:26-33.
- [3] Rosario MLU, Saleh A. Preoperative chemotherapy for congenital hemangiopericytoma and review of the literature. *J Pediatr Hematol Oncol*, 1997; 19(3): 247-250.
- [4] Spitz FR, Bouvet M, Pisters PWT, Pollock RE, Feig BW. Hemangiopericytoma: A 20-year single-institution experience. *Ann Surg Oncol*, 1998; 5(4): 350-355.
- [5] McMaster MJ, Soule EH, Ivins, JC. Hemangiopericytoma. A clinicopathologic study and a long-term follow up of 60 patients. *Cancer*, 1975; 36: 2232-2244.
- [6] Sohda T, Kankatsu Y. Insulin-like growth factor II expression in primary meningeal hemangiopericytoma and its metastasis to the liver accompanied by hypoglycemia. *Hum Pathol*, 1996; 27(8): 858-861.
- [7] Crusco F, Chiodi, M, Pugliese F, Mosca S, Fisher MJ, Lupattelli L. Benign Omental Hemangiopericytoma presenting with hemoperitoneum: radiologic findings. *Am J Roentgenol*, 2005; 184(3): S67-S69.
- [8] Torigoe T, Higure A, Hirata K, Nagata N, Itoh H. Malignant Hemangiopericytoma in the pelvic cavity successfully treated by combined-modality therapy: report of a case. *Surg Today* 2003; 33:479-482.
- [9] Bleicher RJ, Allegra DP, Nora DT, Wood TF, Foshag LJ, Bilchik AJ. Radiofrequency ablation in 447 complex unresectable liver tumors: lessons learned. *Ann Surg Oncol*, 2003; 10(1): 52-53.
- [10] Hatva E, Bohling T, Jaaskelainen J et al. Vascular Growth Factors and receptors in capillary hemangioblastoma and HPC. *Am J Pathol* 1996;148; 763-775.