

HER-2/neu expression in cervical intraepithelial neoplasia and cervical carcinoma

Tessa Joseph* and C.V. Raghuvver

Department of Pathology, Yenepoya Medical College, Yenepoya University, Deralakatte, Mangalore, India

*Correspondence Info:

Dr. Tessa Joseph,
Room no.409,
Gardyenya PG hostel,
Yenepoya Medical College, Lakshmigudde
Deralakatte, Mangalore -575018Karnataka.
E-mail: tessajoseph.613@gmail.com

Abstract

Objectives: 1) To study the expression of HER-2 in Cervical Intraepithelial Neoplasia (CIN) and Cervical carcinoma

2) To correlate expression of HER-2 with histological type, grade and stage of tumor.

Methods: A total of 34 cases were collected during the period from October 2012 to June 2014. Clinical data was collected from medical records. The histopathology slides were analyzed and immunohistochemical (IHC) studies were done on suitable blocks with marker HER-2.

Results: Thirty four specimens including 20 cases of squamous cell carcinoma (58.83%), 4 cases of adenocarcinoma (11.76%) and 10 cases of CIN (29.41%) were analyzed. HER-2 expression was noted in 7 out of 10 cases (70%) of CIN. Out of 12 poorly differentiated squamous carcinomas, 8 showed 3+ positivity and 4 showed 2+ positivity. Amongst the 5 moderately differentiated squamous carcinomas, 3 showed 3+ positivity, 1 showed 2+ positivity and 1 case showed 1+ positivity. Amongst the 3 well differentiated squamous carcinomas, 1 showed 1+ positivity and the remaining 2 showed 2+ positivity. Out of the 4 adenocarcinoma cases, 2 moderately differentiated carcinomas showed 3+ positivity and the remaining 2 well differentiated carcinomas showed 2+ positivity. All FIGO stage 4 cases showed 3+ positivity. Stronger HER-2 expression was also noted among cervical carcinoma cases with lymph node and parametrial involvement.

Conclusions: The intensity of HER-2 expression increased progressively as grade of lesion increased and with presence of lymph node and parametrial involvement. All the cases under FIGO stage 4 showed strong (3+) HER-2 expression.

Keywords: CIN, Cervical carcinoma, IHC, HER-2

1. Introduction

Worldwide, cervical carcinoma is second only to breast carcinoma in its incidence and mortality. About 471,000 new cases are diagnosed every year, mainly among the economically disadvantaged in both developing and industrialized nations.[1] Carcinoma cervix is the most common malignancy in women in India with an incidence of 9 to 44 per 100, 000 women.[2] While curable in early stages, the treatment result of locally advanced disease is still unsatisfactory. Hence the best step to follow would be the development of targeted therapies so as to improve the prognosis of cervical

carcinoma patients.[3] The c-erbB-2 proto-oncogene, also called HER-2/neu, is a gene localized on Chromosome 17q21 and it encodes a growth factor receptor-like molecule with tyrosine kinase activity. Its structure is similar to that of epidermal growth factor receptor and has 1255 amino acids. The expression of HER-2 is believed to be associated with aggressive biological behavior and metastatic potential.[4]

2. Materials and methods

A total of 34 cases were collected during the period from October 2012 to June 2014. Clinical

details and results of imaging studies were collected from the medical records. Routine Haematoxylin and eosin stained slides were evaluated and suitable blocks were selected for immunohistochemistry with HER-2 antibody. Antigen retrieval was done by heating the sections in citrate buffer at P.H 6.0 using pressure cooker. Mouse monoclonal antibody HER-2

(clone CB 11) from NOVOCASTRA Company was used. Standard streptavidin-biotin peroxidase method of IHC was followed. A golden brown membrane and cytoplasmic staining was taken as a positive reaction. Intensity of HER-2 expression was graded according to the 2014 ASCO/CAP guidelines for HER-2 reporting (**Table 1**).

Table 1: The 2014 ASCO/CAP HER-2 Reporting Guideline [5]

Intensity of HER-2 expression	Characteristic features
0	No staining is observed or shows membrane staining that is incomplete and is faint/barely perceptible and within $\leq 10\%$ of tumor cells.
1+	Membrane staining that is incomplete and is faint/barely perceptible and within $>10\%$ of tumor cells.
2+	Circumferential staining that is incomplete and/or weak/moderate within $> 10\%$ of tumor cells. or Complete intense circumferential membrane staining within $\leq 10\%$ of tumor cells.
3+	Complete intense circumferential membrane staining within $> 10\%$ of tumor cells.

3. Results

In the present study age of patients with CIN ranged from 40 to 58 years. The average age at diagnosis was 49.1 years. Age range of patients with cervical carcinoma ranged from 40 to 70 years. The average age at diagnosis was 53.75 years. Thirty four specimens including 10 cases of CIN (29.41%), 20 cases of squamous cell carcinoma (58.83%) and 4 cases of adenocarcinoma (11.76%) were collected. Among 10 cases of CIN there were 7 cases (70%) of CIN-1, 2 cases of CIN-2 (20%) and 1 case of CIN-3 (10%). Among the 7 CIN-1 cases, 3 did not stain with HER-2 while the rest showed 1+ positivity. Both cases of CIN-2 and the single case of CIN-3 showed 2+ positivity. Overall significantly stronger positivity was observed in CIN-2 and CIN-3 cases ($p=0.04$) (**Figure 1 Figure 2**).

Out of 20 cases of Squamous cell carcinoma (SCC), 3 cases (15%) were well differentiated, 5 cases (25%) were moderately differentiated and 12 cases (60%) were poorly differentiated. Among the 3 well differentiated SCC, 1 showed 1+ positivity (**Figure 3**) and the remaining 2 showed 2+ positivity. Out of 5 moderately differentiated SCC, 1 case showed 1+ positivity, another case showed 2+ positivity (**Figure 4**) and remaining 3 showed 3+ positivity (**Figure 5**). Out of 12 poorly differentiated SCC cases, none showed 1+ positivity, 4 showed 2+ positivity and remaining 8 showed 3+ positivity. Overall it was found that among 7 cases of squamous cell carcinoma with 2+ positivity, 2 were (28.6%)

well differentiated, 1 was (14.3%) moderately differentiated and 4 were (57.1%) poorly differentiated. Also out of 11 cases of squamous cell carcinoma with 3+ positivity, 8 were (72.7%) poorly differentiated and 3 were (27.3%) moderately differentiated. However a statistically significant correlation was not established between grade of squamous cell carcinoma and intensity of HER-2 staining ($p=0.165$) (**Table 2**).

Out of 4 cases of adenocarcinoma, both cases of well differentiated adenocarcinoma showed 2+ positivity and both cases of moderately differentiated adenocarcinoma showed 3+ positivity. A significant correlation between HER-2 staining and grade of adenocarcinoma was not established (Yates $p=0.317$).

Out of 24 cervical carcinoma cases, 3 cases (12.5%) were of FIGO stage 1, 11 cases (45.8%) were of FIGO stage 2, 7 cases (29.2%) were of FIGO stage 3 and 3 cases (12.5%) were of FIGO stage 4. Among the 3 cases under stage 1, one showed 2+ positivity and remaining 2 showed 3+ positivity. Out of 11 cases under stage 2, one showed 1+ positivity, 5 showed 2+ positivity and remaining 5 showed 3+ positivity. Of the 7 cases under stage 3, one showed 1+ positivity, 3 showed 2+ positivity and remaining 3 cases showed 3+ positivity. All cases under stage 4 showed 3+ positivity. However statistically significant correlation between intensity of HER-2 expression and stage of cervical carcinoma could not be established ($p= 0.71$) (**Table 3**).

Among carcinoma cases it was found that 4 cases (16.7%) had no parametrial or lymph node involvement, 11 cases (45.8%) had only parametrial involvement and 9 cases (37.5%) had involvement of both. On analyzing variation in intensity of HER-2 staining with lymph node and parametrial involvement it was found that among 9 cases with 2+ positivity, 2 cases had no lymph node or parametrial involvement, 4 cases had only parametrial involvement and 3 of the cases showed both. Out of

13 cases with 3+ positivity, 2 cases had no lymph node or parametrial involvement, 5 cases had only parametrial involvement and remaining 6 cases had involvement of both. Even though cervical carcinoma cases with involvement of lymph node and parametrium showed stronger HER-2 staining a statistically significant correlation between these variables could not be established ($p=0.577$) (Table 4).

Table 2: HER-2 expression in various grades of Squamous cell carcinoma of cervix

Grade of Squamous cell carcinoma		Intensity of HER-2 expression			Total
		1+	2+	3+	
Well differentiated	Count	1	2	0	3
	Percentage	(50%)	(28.6%)	(0%)	(15%)
Moderately differentiated	Count	1	1	3	5
	Percentage	(50%)	(14.3%)	(27.3%)	(25%)
Poorly differentiated	Count	0	4	8	12
	Percentage	(0%)	(57.1%)	(72.7%)	(60%)
Total	Count	2	7	11	20
	Percentage	(100%)	(100%)	(100%)	(100%)

Table 3: HER-2 expression among cervical carcinoma cases under various FIGO stages

FIGO stage of tumor		Intensity of HER-2 expression			Total
		1+	2+	3+	
Stage 1	Count	0	1	2	3
	Percentage	(0%)	(11.1%)	(15.4%)	(12.5%)
Stage 2	Count	1	5	5	11
	Percentage	(50%)	(55.6%)	(38.5%)	(45.8%)
Stage 3	Count	1	3	3	7
	Percentage	(50%)	(33.3%)	(23.1%)	(29.2%)
Stage 4	Count	0	0	3	3
	Percentage	(0%)	(0%)	(23.1%)	(12.5%)
Total	Count	2	9	13	24
	Percentage	(100%)	(100%)	(100%)	(100%)

Table 4: Correlation of HER-2 expression with lymph node and parametrial involvement

Lymph node and parametrial involvement		Intensity of HER-2 expression			Total
		1+	2+	3+	
Both absent	Count	0	2	2	4
	Percentage	(0%)	(22%)	(15.4%)	(16.7%)
Parametrium alone	Count	2	4	5	11
	Percentage	(100%)	(44.4%)	(38.5%)	(45.8%)
Both present	Count	0	3	6	9
	Percentage	(0%)	(33.3%)	(46.2%)	(37.5%)
Total	Count	2	9	13	24
	Percentage	(100%)	(100%)	(100%)	(100%)

Figure 1: Photomicrograph of HER-2 antigen negativity in CIN-1 (HER-2, 40X)




Figure 2: Photomicrograph of HER-2 antigen 2+positivity in CIN-2 (HER-2, 10X)

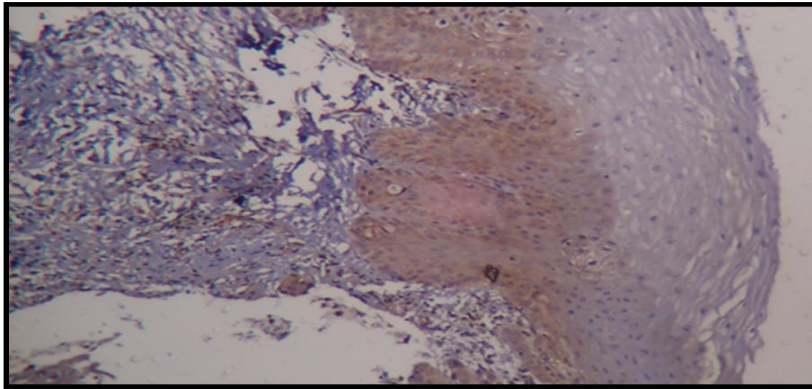


Figure 3: Photomicrograph of HER-2 antigen 1+ positivity in well differentiated Squamous Cell Carcinoma (HER-2, 10X)

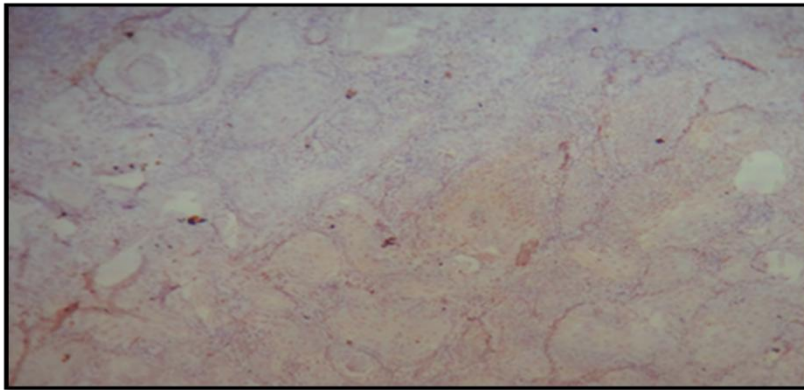


Figure 4: Photomicrograph of HER-2 antigen 2+ positivity in moderately differentiated Squamous cell carcinoma (HER-2, 40X)

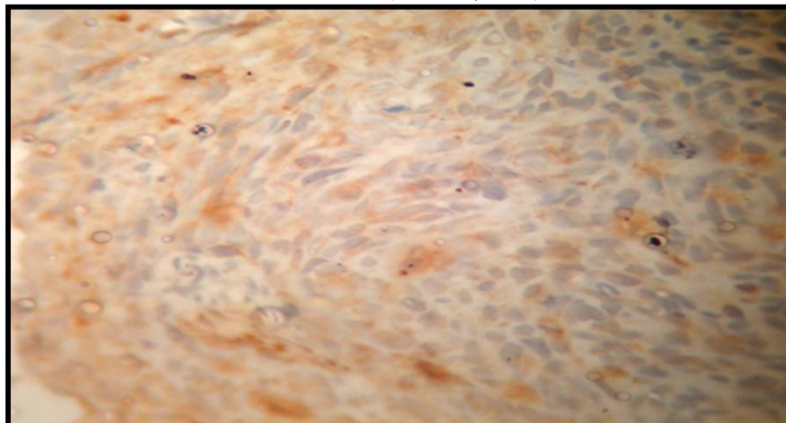
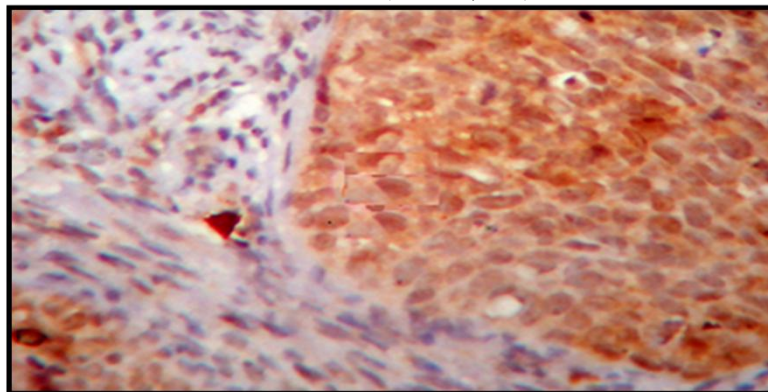


Figure 5: Photomicrograph of HER-2 antigen 3+ positivity in moderately differentiated Squamous cell carcinoma (HER-2,40X)



4. Discussion

Ten cases of CIN were encountered in the present study. HER-2 positivity was noted in 7 out of 10 (70%) CIN cases. A significant correlation was noted between intensity of HER-2 stain and type of CIN ($p=0.040$). In contrast to the present study HER-2 expression was noted only in 37.5% of CIN cases by Li *et al*[6], while 60% of CIN cases showed HER-2 positivity in a study by Gupta *et al*[7]. Protrka *et al*[8] reported HER-2 expression in 66% of CIN cases. Lakshmi *et al*[9] noticed HER-2 expression in 86.25% of CIN cases and this was found to be statistically significant.

In the present study HER-2 expression was noticed in all 24 cases (100%) of cervical carcinoma. According to various studies expression of HER-2 in cervical carcinoma varied from 12.1% to 96.8%.⁶⁻¹⁸ This variability may be attributed to the difference in number of cases analyzed, variation in stage of tumor and in the experimental procedure followed. Costa *et al*[12] reported HER-2 expression in 77% of cervical carcinomas while Lakshmi *et al*[9] reported HER-2 expression in 96.8% of squamous cell carcinomas of cervix.

Only Squamous cell carcinoma belonging to well differentiated and moderately differentiated categories showed 1+ positivity whereas 3+ positivity was detected only in Squamous cell carcinoma belonging to moderately differentiated and poorly differentiated categories. Also among 11 cases with 3+ positivity, 8 cases (72.7%) were poorly differentiated while remaining 3 cases (27.3%) were moderately differentiated. But a statistically significant correlation was not established between HER-2 expression and grade of SCC ($p=0.165$). Similar to the present study Mandai *et al*[13] and Ray *et al*[14] also did not find any correlation between HER-2 expression and grade of SCC.

In the present study 4 cases of adenocarcinoma were analyzed. Both cases of well differentiated adenocarcinoma showed 2+ positivity while both cases of moderately differentiated adenocarcinoma showed 3+ positivity. However a significant correlation was not established between HER-2 expression and grade of adenocarcinoma (Yates $p=0.317$). Similar to this study Mandai *et*

al[13] and Kihana *et al*[15] also did not find any relation between HER-2 expression and grade of adenocarcinoma.

In the present study stronger HER-2 expression was noted in FIGO stage 2 tumors. On analysis it was found that higher intensity of HER-2 expression among cases under stage 2 was due to the presence of poorly differentiated carcinomas under it. Also both cases under stage 1 which showed 3+ positivity were cases of poorly differentiated Squamous cell carcinoma. A statistically significant relationship was not established between HER-2 expression and stage of the tumor. Contrary to this Gupta *et al*[7] and Ndubisi *et al*[16] found a significant correlation between HER-2 expression and higher stage of cervical carcinoma. Gupta *et al*[7] had analyzed 65 cases of cervical carcinoma while Ndubisi *et al*[16] had studied HER-2 expression in 150 cases of cervical carcinoma. The discordance between the present study and other studies could be due to the small number of cases analyzed in the present study.

In the present study out of 24 cases of cervical carcinoma, 4 cases had no lymph node or parametrial involvement, 11 cases had only parametrial involvement while 9 cases had both parametrial and lymph node involvement. Even though cases with parametrial and lymph node involvement showed higher percentage of tumor cells with stronger HER-2 expression a statistically significant correlation was not established between these parameters ($p=0.577$). Mandai *et al*[13] and Yong *et al*[17] analyzed HER-2 expression in 39 and 74 cases of cervical adenocarcinoma respectively and stated that a significant correlation existed between HER-2 expression and lymph node metastasis. Gupta *et al*[7] analyzed HER-2 expression in 65 cases of cervical carcinoma and stated that intensity of staining correlated with presence of parametrial extension and lymph node metastasis. The discordance between the present study and the above mentioned studies could be due to the less number of cases analyzed.

Overall stronger HER-2 expression was seen in cases of malignant tumors when compared to premalignant lesions. A gradual progression in HER-2 expression was noticed as lesions moved up the

spectrum. Similar finding were reported by Gupta *et al*[7] and Lakshmi *et al*[9].

Kim *et al*[18] stated that HER-2 expression in cervical carcinoma was an independent prognostic factor. In the present study HER-2 expression did not correlate significantly with grade of the tumor, stage at presentation or with presence of parametrial and lymph node involvement. As stronger HER-2 expression was noted among poorly differentiated tumors and those with parametrial and lymph node involvement it can be deduced that HER-2 expression in cervical carcinomas is a poor prognostic factor.

5. Conclusion

In the present study HER-2 expression was noted in 7 out of 10 cases of CIN (70%) and in all 24 cases (100%) of cervical carcinoma. The intensity of HER-2 expression increased progressively as grade of lesion increased and with presence of lymph node and parametrial involvement. All the cases under FIGO stage 4 showed strong (3+) HER-2 expression. Some of the cases under FIGO stage 1 and stage 2 also showed strong (3+) HER-2 expression but this was due to the presence of poorly differentiated carcinomas under these groups. However a statistically significant correlation was not established between HER-2 expression and the various parameters that was analyzed namely grade of tumor, stage of tumor and presence of lymph node and parametrial extension.

References

- [1] Cheah P, Looi L. Carcinoma of the uterine cervix: a review of its pathology and commentary on the problem in Malaysians. *Malaysian J Pathol.* 1999; 21(1):1 – 15.
- [2] Wadhvani R, Bamnia R, Meena M. Clinico-pathological analysis of cancer cervix in tertiary care centre. *J Evol Med Den Sci.* 2013; 2(39):7381-7385.
- [3] Dueñas-Gonzalez A, Cetina L, Mariscal I, de la Garza J. Modern management of locally advanced cervical carcinoma. *Cancer Treat Rev.* 2003; 29:389-399.
- [4] Vaidyanathan K, Kumar P, Reddy CO, Deshmane V, Somasundaram K, Mukherjee G. ErbB-2 expression and its association with other biological parameters of breast cancer among Indian women. *Indian J Canc.* 2010; 47(1):8-15.
- [5] Wolff AC, Hammond MEH, Hicks DG, Dowsett M, McShane LM, Allison KH, *et al.* Recommendations for Human Epidermal Growth Factor Receptor 2 Testing in Breast Cancer. American Society of Clinical Oncology/College of American Pathologists Clinical Practice Guideline Update. *Arch Pathol Lab Med.* 2014; 138: 241–256.
- [6] Li G, Yu D, Zhong-Qiu W. Significance of EGFR, HER-2 and VEGF expressions in cervical intraepithelial neoplasia and squamous cell carcinoma. *Cancer Res Clin.* 2013; 25(11): 750-753.
- [7] Gupta N, Singh S, Marwah N, Kumar S, Chabra S, Sen R. HER-2/neu expression in lesions of uterine cervix: Is it reliable and consistent? *Indian J Pathol Microbiol.* 2009; 52:482-485.
- [8] Protrka Z, Mitrović S, Arsenijević N, Baskic D, Radosavljevic G, Stankovic M, *et al.* HER-2 expression in uterine cervix carcinogenesis. *J BUON.* 2007; 12(1): 91-97.
- [9] Lakshmi S, Nair MB, Jayaprakash PG, Rajalekshmy TN, Nair MK, Pillai MR. c-erbB-2 oncoprotein and epidermal growth factor receptor in cervical lesions. *Pathobiology.* 1997; 65:163–168.
- [10] Kristensen GB, Holm R, Abeler VM, Trope CG. Evaluation of the prognostic significance of cathepsin D, epidermal growth factor receptor, and c-erbB-2 in early cervical squamous cell carcinoma. An immunohistochemical study. *Cancer.* 1996; 78: 433-440.
- [11] Nevin J, Laing D, Kaye P, McCulloch T, Barnard R, Silcocks P, *et al.* The significance of Erb-b2 immunostaining in cervical cancer. *Gynecol Oncol.* 1999; 73: 354-8.
- [12] Costa MJ, Walls J, Trelford JD. c-erbB-2 oncoprotein over-expression in uterine cervix carcinoma with glandular differentiation. A frequent event but not an independent prognostic marker because it occurs late in the disease. *Am J Clin Pathol.* 1995; 104: 634–642.
- [13] Mandai M, Konishi I, Koshiyama M, Komatsu T, Yamamoto S, Nanbu K, *et al.* Altered expression of nm23-H1 and c-erb B-2 proteins have prognostic significance in adenocarcinoma but not in squamous cell carcinoma of the uterine cervix. *Cancer.* 1995; 75:2523-2529.
- [14] Ray A, Naik SL, Sharma BK. Distribution of prognostically unfavourable product of C-erb B-2 oncogene and EGFR in carcinomas of the breast and uterine cervix. *Indian J Physiol Pharmacol.* 2002; 46(4): 423-33.
- [15] Kihana T, Tsuda H, Teshima S, Nomoto K, Tsugane S, Sonoda T, *et al.* Prognostic significance of the over expression of c-erbB-2 protein in adenocarcinoma of the uterine cervix. *Cancer.* 1994; 73: 148-153.
- [16] Ndubisi B, Sanz S, Lu L, Podczaski E, Benrubi G, Masood S. "The prognostic value of HER-2/neu oncogene in cervical cancer". *Ann Clin Lab Sci.* 1997; 27(6): 396-401.
- [17] Yong H, Shumo C, Shaoyin Y, Daren S. Expression of c-erbB-2 and PCNA in cervical adenocarcinoma and its signification. *Chin J Canc Res.* 1998; 10(1): 68-70.
- [18] Kim YT, Kim SW, Yoon BS. Expression of c-erbB-2 oncoprotein and the prognosis of patients with cervical carcinoma. *Int J Gynecol Obstet.* 2006; 92(2): 151-152.