

Research Article

Assessment of oral acute toxicity (LD₅₀) of “Green Health Herbal mixture” in Wistar albino rats

Adumanya, OCU^{*1}; Obiloma, AA² and Iwuanyanwu, C¹

¹Department of Science Laboratory Tech., Imo State Polytechnic, Umuagwo, Imo State, Nigeria

²Department of Nutrition and Dietetics, Imo State Polytechnic, Umuagwo, Imo State, Nigeria

***Correspondence Info:**

Adumanya, OCU
Department of Science Laboratory
Tech., Imo State Polytechnic,
Umuagwo, Imo State, Nigeria
Email: adumso2@yahoo.com

Keywords:

Toxicity, Herbal,
Oral,
Photomicrograph,
Necrosis,

Abstract

“Green Health herbal mixture” is a pharmacological pure herb product of Green Healthcare Limited, Aboha, Ohii, Imo State, Nigeria, approved by National Agency for Food and Drug Administration and Control (NAFDAC) used orally and topically in the treatment of muscular ache/pain, scalp, warts, inflammation, skin infection due to bacteria/fungi, and lumps and to relieve high fever. However, its oral lethal dose is yet to be reported. Thus, this work was aimed at assessing its oral acute toxicity in *wistar* albino rats. The results of phase **one** and phase **two** of the study showed no mortality in any of the groups of rats in 24 hours, 72 hours and up to two weeks after oral administration of 5000 mg per kg body weight (b.w) of the herbal mixture, but the histology (photomicrograph) of the liver sections revealed multiple dose-dependent necrosis, histological lesions, and abnormal sinusoids. Therefore, oral intake of the herbal mixture at dose less than or equal to 5000 mg/kg b.w. is safe, but may not be advisable, having noted its deleterious effects on the hepatocytes via the photomicrograph (H & E 400). That is oral LD₅₀ > 5000 mg/kg b.w. Hence, topical usage is recommended.

1. Introduction

Green health herbal mixture is a mixture of pure herbs which is used to relief muscular ache/pain, inflammation, for the treatment of skin infection, lumps and relief of high fever. Medicinally, the balm is a mixture of pure herbs and leaves (*Piper guineense* – 25%, *Moringa oleifera* – 20%, *Vitellaria paradoxa* – 10%, Bee wax – 25%, Bee oil – 20%) which are known for their medicinal benefits, nutrition and healing properties [1-7].

The amount of pharmacological substances and chemicals being used in the human community today, have increased to almost an innumerable amount [8]. These may be presented today in the form as constituents of food substances, medicines, and beverages, other industrial and household products. However, these chemicals or pharmacological substances may result in chronic toxicity in the lining system when used over a long period of time or acute toxicity may also occur when large quantities capable of eliciting immediate toxic effect are used [8]. These effects may be mild or severe, depending on the nature of the substance. Acute toxicity is defined as the unwanted effect(s) that occur either immediately or at a short time interval after a single or multiple administrations of such substances within 24 hours. The unwanted (or adverse) effect is any effect that produces functional impairments in organs and/or biochemical lesions, which could alter the functioning of the organism in general or individual organs [9].

A study of acute toxicity however tends to establish the dose-dependent unwanted effect, which may take place and this, includes all information that is important in the assessment of acute toxicity including mortality. The assessment of the lethal dose (LD₅₀) (the dose that kills 50% of test animals population) has now been used as a major parameter in measuring acute toxicity and also as an initial procedure for general screening of chemical and pharmacological agents for toxicity [8].

Apart from mortality, other biological effects and the time of onset, duration and degree of recovery of survived animals, are also important in acute toxicity evaluation. Acute toxicity study solely gives information about LD₅₀, therapeutic index and the degree of safety of pharmacological agents [8]. The toxicity assessment of pharmacological agents is a very important procedure that is usually carried-out before they are allowed to enter the market for sale. The LD₅₀ can be found for any route of entry or administration, but dermal (interperitoneal) and oral administration methods are the most common [10]. The LD₅₀ value obtained at the end of the experiment is LD₅₀. The results of oral studies are important for drugs, food and accidental domestic poisonings [10]. In general, the smaller the LD₅₀ value, the more toxic the chemical is, while the large the LD₅₀ value, the lower the toxicity [11].

Therefore, the aim of this research work is to determine the oral LD₅₀ value of “Green health herbal mixture” so as to encourage or otherwise it’s oral used.

2. Materials and Methods

2.1 Procurement of Wistar Albino Rats

Healthy wistar albino rats of both sexes weighing between 44.18- 85.68 g were obtained from the Animal House of Department of Science Laboratory Technology, Imo State Polytechnic, Umuagwo-Ohaji, Imo State, Nigeria. The animals were kept in plastic cages and allowed to acclimatize for a period of one week before the commencement of the study. They were allowed unrestricted access to standard feed (Vital feed growers) obtained from Brand Cereals and Oil Mills Ltd, Bukuru, Jos, Nigeria and water *ad libitum* throughout the experimental period. The rats were handled in accordance with the guidelines for the care and use of laboratory animals [12].

2.2 Acute toxicity (LD₅₀) study of the herbal mixture

The method of Lorke [13](1983) was used to determine the LD₅₀ of “Green health herbal mixture”. The “Green health herbal mixture” was administered orally using sterile orogastric tubes.

Then the LD₅₀ is calculated by the formula

$$LD50 = \sqrt{D0 * D100}$$

D₀ = Highest dose that gave no mortality

D₁₀₀ = Lowest dose that produce mortality

2.3 Evaluation of the lethal dose

2.3.1 Experimental design for the lethal dose study

The wistar albino rats were weighed and sorted into three groups of three rats each in **Phase one**, one group of three rats as the control and three groups of one rat each in **phase two**, such that their average weights were approximately equal. The rats were kept in plastic cages in the Animal House of the Department of Science Laboratory Technology, Imo State Polytechnic Umuagwo-Ohaji, Imo State and allowed to acclimatize for a period of one week before the commencement of the study. They were allowed unrestricted access to standard feed (Vital feed growers) obtained from Brand Cereals and Oil Mills Ltd, Bukuru, Jos, Nigeria and water *ad libitum* throughout the experimental period. The rats were handled in accordance with the guidelines for the care and use of laboratory animals [12]. Each group in phase one were administered 10 , 100 and 1000 mg single dose of the herbal mixture respectively, while each group in phase two received 1600, 2900 and 5000 mg single dose of the herbal mixture respectively. The control group received 5 ml/kg b.w (0.1 mL) single dose normal saline.

2.4 Histology Study

The rats were sacrificed through humane killing and their livers obtained and stored with 40% formalin. This was later processed and embedded into paraffin wax. The tissue block sectioned into 5µm, was later stained with heamatoxylin and eosine and their photomicrograph taken.

3. Results

3.1 Oral acute effect of the herbal mixture in wistar albino rats.

The phase I and phase II of the oral acute effect of the herbal mixture is presented in Table 1. The results showed that no mortality was recorded at various doses of the herbal mixture used both in the phase I and phase II of the study using the method of Lorke [13].

3.2 Effect of oral acute administration of the herbal mixture on the body weights of the albino rats

Table 2 showed that there were marked significant changes in the body weights of the albino rats both in the phase I and phase II of study. There was significant decrease in the weights of the rats administered with various doses of the herbal mixture as shown in Table 2.

3.3 Histology study of the liver of the experimental rats

The photomicrograph of the liver showed mild degenerated hepatocytes as shown in the figure 1 below.

Table 1: Mortality recorded in oral lethal dose (LD₅₀) determination of the herbal mixture

Experiment	Dose (mg/kg body weight)	No. of Dead rats after 24 hrs	No. of Dead rats after 72 hrs
Phase 1	10	<u>0</u>	<u>0</u>
		3	3
	100	<u>0</u>	<u>0</u>
		3	3
	1000	<u>0</u>	<u>0</u>
		3	3
Control	0	<u>0</u>	<u>0</u>
		3	3
Phase 2	1600	<u>0</u>	<u>0</u>
		1	1
	2900	<u>0</u>	<u>0</u>
		1	1
	5000	<u>0</u>	<u>0</u>
		1	1

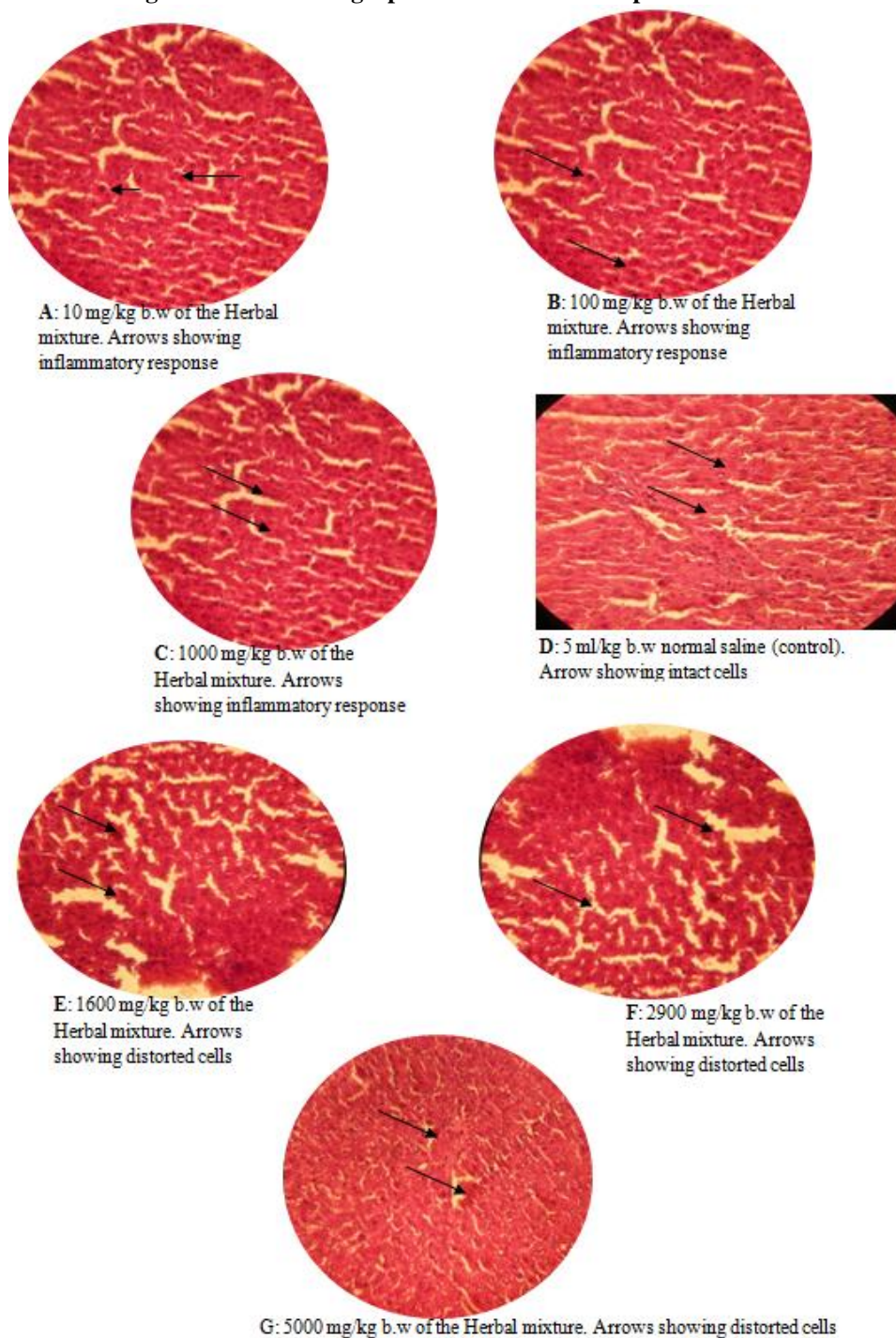
Keys:

- 0 = Number of Deaths
 3 = Number of *Wistar* albino rats used in the experiment
 1 = Number of *Wistar* albino rats used in the experiment

Table 2: Effect of the acute toxicity study of the herbal mixture on the *wistar* albino rats weights

Experiment	Dose (mg/kg body weight)	Mean weight (g) (0 hr) before administration	Mean weight (g) after 24 hrs	Mean weight (g) after 72 hrs
Phase 1	10	44.18	34.18	30.82
	100	65.89	57.79	49.96
	1000	77.95	66.76	58.42
Control	0	85.68	90.02	95.68
	1600	69.79	61.53	56.78
Phase 2	2900	75.99	69.31	64.81
	5000	84.02	77.67	67.98

Values in the same rows are significant at ($P > 0.05$).

Figure 1: Photomicrograph of the liver of the experimental rats

4. Discussion

The results of the acute toxicity study of “Green health herbal mixture” (Table 1), showed that no mortality was recorded in any of the experimental groups of albino rats in 24 hours, 72 hours and up to two weeks after oral administration of 5000mg per kg body weight. This work is in agreement with Hodge and Sterner [14](2005) and Lorke [13] (1983) reports, but the histology or photomicrograph of the liver as shown in the Figure 1 compared to the control showed dose - dependent necrosis, histopathological lesion and slight degenerative changes in the liver cells (H and E 400). Some signs of toxicity like dizziness and inactivity were noticed initially and weight loss was also observed (Table 2). This may suggest the deleterious effect of the herbal mixture and that the “Green health herbal mixture” is hepatotoxic.

5. Conclusion

Oral intake of the herbal mixture at dose less than or equal to 5000 mg/kg b.w. is safe, but may not be advisable, having noted its deleterious effects on the hepatocytes via the photomicrograph (H & E 400). That is oral LD₅₀ > 5000 mg/kg b.w. Hence, topical usage is recommended.

Conflict of interest: None

References

- [1] Edward, T. "Waxes, Animal and Vegetable. Beewax", A Directory of Applied Chemistry, Vol. (5), Revised and Enlarged edition, Longmans, Green, and Co, London, 1916: P. 737.
- [2] Brown, R.H. Beeswax (2nd edition) Bee books New and old burrow bridge, Somerset UK. 1981:15 - 20.
- [3] Schwarz, D. "Water Clarification Using *Moringa Oleifera*" Technical Information W1e (Gate Information Service) 2000. Retrieved from <http://www.deutsch.aethiopischer-verein.de> on 26/09/2011.
- [4] Maranz, S.; Wiesman, Z.; Bisgaard, J. and Bianchi, G. "Germplasm Resources of *Vitellaria paradoxa* based on variations in fat composition across the species distribution range". Agroforestry Systems, (Kluwer Academic Publishers) 2004; 60(1): 71-76.
- [5] Martins, C. Uziza (*Piper Guineense*) Local Food Condiments in Nigeria. Retrieved [MartinsLibrary.blogspot.com/home/foodScience Technology](http://MartinsLibrary.blogspot.com/home/foodScience%20Technology). 2007 On 25/03/2011.
- [6] Schill, S.R. (2008). "Multidimensional Moringa; Biodiesel Magazine. Retrieved from Sretkaschill@bbibiofuels.com on 26/09/2011.
- [7] Les, C. Top-Bar Keeping: Organic Practices for Honey bee Health. *Chealsea Green Publishing* 2012: Pp. 10 – 15.
- [8] Chiendu, E.; Arome, D.; and Ameh, F.S. A New method for Determining Acute Toxicity in Animal Models, *Toxicology International Journal*, 2013; 20 (3): 224-226.
- [9] Akhila, J.S.; Deepa, S. and Alwar, M.C. Acute Toxicity Studies and Determination of medium Lethal dose, *Curr. Sci.* 2007; 9: 917- 20.
- [10] Adumanya, O.C.; Uwakwe, A.A. and Essien, E.B. (2014). Acute Toxicity (LD₅₀) study of methanol extract of *Salacia senegalensis* Lam (DC) leaf on albino mice, *International Journal of Current Research in Chemistry and Pharmaceutical Sciences*, 1 (4): 20 - 23.
- [11] Senin, R. (2006). Acute Toxicity Study. Retrieved from ([http://www.\(Cohs.ca/oshanswers/chemicals/Ido50.html](http://www.(Cohs.ca/oshanswers/chemicals/Ido50.html)) on 27/3/2010.
- [12] United States of America National Research Council (US-NRC) (2003). Guidelines for the Care and Use of Laboratory Animals. 8th edition. Washington, DC, USA: National Academic Press.
- [13] Lorke, D. A New Approach to Practical Acute-Toxicity Testing. *Arch, Toxicol.*, 1983; 53: 275- 289.
- [14] Hodge, A, and Sterner, B. (2005). Toxicity Classes in Canadian Centre for occupational Health and Safety. Retrieved from (<http://www.ccdis.ca/osha-nswers/chemcials/id50.htm>) on 3/5/2010.
- [15] Marters, E.T; Yidame, J.A.; and Lowett, P.N. (2010). 'Trade and Sustainable Forest Management'. Retrieved from <http://www.fao.org> on 14/9/2010.